Physiatrist's Voice

NEWSLETTER December 2025

Enhancing Health And Function Through Education And Research In The Field Of Physical Medicine And Rehabilitation

In this Issue

1. President's Message
2. Save the Date
3. Deep-Seated Post-Traumatic Osteomyelitis Following Open Femur and Tibia Fractures: Case Report and Literature Review
   - Craig Lichtblau MD
4. Osteomyelitis—
   Craig Lichtblau MD
5. Blood Flow Restriction Training in Sports Rehabilitation
   - Clay Moss, MD
6. Residency Updates:
   - U Miami
   - Broward Health
   - UCF/HCA FL West
   - U Florida
   - Memorial Healthcare
   - Larkin Community Hospital
7. PM&R Pioneers
8. Professional Opportunities
9. Newsletter Information and Disclaimers

PRESIDENT'S MESSAGE
Diana Hussain MD
President FSPMR

Diana A. Hussain, M.D.

Dear Colleagues,

As we reach the end of 2025, I find myself reflecting with gratitude and pride on everything we have accomplished together. This has been a year of renewed energy, deeper collaboration, and remarkable progress for our society and our specialty. I want to sincerely thank each of you for your dedication, your advocacy, and your unwavering support of the Florida Society of Physical Medicine & Rehabilitation.

A Major Milestone: Our Own Independent FSPMR Annual Meeting

It is with tremendous excitement that I share a historic development for our society:

In 2026, FSPMR will hold our own independent, stand-alone Annual Meeting in Orlando.

For the first time in many years, we will gather under the FSPMR banner alone — with a program created exclusively for physiatrists, designed around the interests, needs, and vision of our specialty.

Exact dates and details will be announced soon, but I can assure you this meeting will represent the next chapter of growth and identity for FSPMR. It will be a place where education, innovation, advocacy, and community come together in a way that truly reflects who we are and what we stand for.

Physiatrist's Voice
NEWSLETTER December 2025

Our Goals for 2026

As we prepare for the year ahead, I want to outline several key goals that will guide our mission, strengthen our influence, and elevate the presence of PM&R in Florida.

1. Strengthen Our Identity as Physiatrists

With our independent meeting, we will highlight the full scope of our specialty — from interventional pain and regenerative medicine to neurorehabilitation, musculoskeletal medicine, sports, spasticity, and inpatient care.

Our goal is to make FSPMR the home for every physiatrist in Florida.

2. Expand Educational Opportunities

In 2026, we aim to:

- Launch additional virtual lectures and case-based webinars
- Increase collaboration with Florida residency programs
- Develop hands-on workshops tailored exclusively for PM&R practice
- Promote leadership pathways for residents and early-career physiatrists

3. Grow Membership & Engagement

We will continue to welcome physiatrists from all practice models — inpatient, outpatient, academic, pain, and sports.

Our objective is not only to grow membership numbers, but to build a stronger, more connected community.

4. Strengthen Advocacy & PAC Support

FSPMR will deepen its involvement in the FMA and other state-level advocacy initiatives.

Building a stronger PAC presence is essential for protecting our scope, improving patient access, and ensuring physiatrists have a voice in policy decisions that affect our daily practice.

5. Celebrate Our Legacy & Leadership

After launching the Hall of Fame in 2024, we will continue honoring leaders who have shaped our society.

In 2025, we proudly inducted:

- Lorry Davis, whose decades of service as Executive Director provided foundational support for our society
- Mitchell Freed, MD, recognized for his long-standing dedication to PM&R in Florida

In 2026, we will further recognize those whose commitment has strengthened our specialty's presence across the state.

6. Foster a More Visible Public Presence

To enhance the impact of our specialty, we will work toward:

- A refreshed website
- Increased social media outreach
- Public education efforts that highlight the role of physiatrists in restoring function, independence, and quality of life

Physiatrist's Voice
NEWSLETTER December 2025

Looking Back With Gratitude — and Ahead With Enthusiasm

This year reminded us that when we stay engaged, we grow stronger. Our presence at the FMA, our participation in multidisciplinary initiatives, our residents' involvement, and our thriving community all show that FSPMR is not just a society — it is a movement.

As we enter the holiday season, I hope each of you finds moments of rest, joy, and connection with loved ones. I am deeply grateful for the privilege of serving as your president, and I look forward to the incredible year ahead as we prepare to launch our first independent FSPMR Annual Meeting.

Thank you for your commitment, your passion, and your leadership.

Let's continue building the future of physiatry — together.

Warm regards,

Diana Hussain, M.D. FAAPMR,DABPM

President, FSPMR

Physiatrist's Voice

NEWSLETTER December 2025

SAVE THE DATE:
OCTOBER 9/10

1st Annual
Florida Society of Physical Medicine and Rehabilitation focused meeting

Innovations in P M & R

LAKE NONA WAVE HOTEL
6100 WAVE HOTEL DRIVE
ORLAND, FL 32827

Thank you to our Sponsors:

OPEN ACCESS Freely available online

International Journal of Physical Medicine & Rehabilitation

Case report

Deep-Seated Post-Traumatic Osteomyelitis Following Open Femur and Tibia Fractures: Case Report and Literature Review

Craig H. Lichtblau[1,2*], Stephen Quinnan[3], Jaroslaw Michal Deszczynski[4], Gabrielle Meli[5], Marta Walachowska[6], Michalina Prowotorow[7]

[1]Medical Director, Osseointegration Program, Physical Medicine and Rehabilitation Consultant to the Paley Orthopedic and Spine Institute at St. Mary's Medical Center, West Palm Beach, Florida, USA; [2]Consultant to Children's Medical Services for the State of Florida, Florida, USA; [3]Orthopedic Surgeon, Paley Orthopedic and Spine Institute at St. Mary's Medical Center, West Palm Beach, FL, USA; [4]Department of Orthopaedics and Rehabilitation, Medical Dentistry Faculty, Medical University of Warsaw; [5]University of Miami Miller School of Medicine, Miami, FL, USA; [6]University of Milan School of Medicine, Milan, Italy; [7]Medical University of Lodz, Lodz, Poland

ABSTRACT

Osteomyelitis, a difficult to treat inflammation of bone and marrow, poses substantial challenges due to biofilm formation, relative avascularity, hardware involvement, and high recurrence risk. *Staphylococcus aureus* remains the most common causative pathogen, though a wide range of bacteria, mycobacteria and fungi may be implicated. Diagnosis integrates clinical features, laboratory markers, imaging, and bone biopsy, the latter remaining the gold standard for pathogen identification. Management strategies typically combine prolonged antimicrobial therapy with surgical debridement and, when necessary, reconstructive techniques or amputation. Adjunctive measures such as local antibiotic delivery and hyperbaric oxygen therapy may support outcomes in refractory cases. We present a complex case of post-traumatic osteomyelitis in a 65 year old man with high-energy open fractures of the femur and tibia sustained in a motor vehicle accident. His prolonged course required multiple surgical interventions, vascular repair, hardware removal, antibiotic spacers and hyperbaric oxygen therapy, complicated by persistent infection, chronic pain, and neurocognitive deficits. This case underscores the multifactorial challenges of osteomyelitis management and highlights the need for coordinated multidisciplinary care to optimize outcomes.

Keywords: Osteomyelitis; Physical Medicine; Rehabilitation; Infection; Amputation

INTRODUCTION

Osteomyelitis, an inflammation of bone and marrow that is usually bacterial in origin, is notoriously difficult to manage [1,2]. It is associated with prolonged treatment, recurrent disease, and substantial cost [2,3]. Critical complicating factors include the bone's relative avascularity, the propensity for biofilm formation, and the involvement of hardware, each of which contribute to treatment resistance and functional decline [4,5].

Here, we review the epidemiology, pathophysiology, diagnosis and management of osteomyelitis. We then present a case study of a 65-year-old man who sustained high-energy open fractures of the femur and tibia after being pinned under a vehicle, ultimately developing a deep-seated bone infection requiring multiple surgical interventions and prolonged antimicrobial therapy.

Osteomyelitis may be caused by different pathogens and show distinct clinical presentations

The predominant pathogen in osteomyelitis, accounting for 40 to 60 percent of cases, is *Staphylococcus aureus* [1,2]. Other relevant pathogens include coagulase-negative staphylococci (especially in prosthetic infections), *streptococci*, Gram-negative bacilli such as *Pseudomonas aeruginosa*, anaerobes in diabetic foot infections, mycobacterial species, and, less commonly, fungi [2,6].

Correspondence to: Craig H. Lichtblau, Medical Director, Osseointegration Program, Physical Medicine and Rehabilitation Consultant to the Paley Orthopedic and Spine Institute at St. Mary's Medical Center, West Palm Beach, Florida, USA, E-mail: c.lichtblau@chlmd.com

Received: 21-Aug-2025, Manuscript No. JPMR-25-38565; **Editor assigned:** 25-Aug-2025, PreQC No. JPMR-25-38565 (PQ); **Reviewed:** 08-Sep-2025, QC No. JPMR-25-38565; **Revised:** 15-Sep-2025, Manuscript No. JPMR-25-38565 (R); **Published:** 22-Sep-2025, DOI: 10.35248/2329-9096.25.13.758.

Citation: Lichtblau C, Quinnan S, Deszczynski J, Meli G, Walachowska M, Prowotorow M (2025). Deep-Seated Post-Traumatic Osteomyelitis Following Open Femur and Tibia Fractures: Case Report and Literature Review. Int J Phys Med Rehabil. 13:758.

Copyright: © 2025 Lichtblau C, et al. This is an open-access article distributed under the terms of the Creative Commons Attribution License, which permits unrestricted use, distribution and reproduction in any medium, provided the original author and source are credited.

Osteomyelitis pathogenesis involves bacterial colonization of bone, microbial invasion of osteocytes and activation of host inflammatory responses leading to vascular compromise and necrosis [2,4]. Biofilm formation enables persistent infection and resistance to treatment, while sequestra (necrotic bone fragments) act as bacterial sanctuaries, necessitating surgical removal for resolution [4].

There are multiple frameworks for classifying osteomyelitis. Waldvogel classification stratifies osteomyelitis by duration (acute *versus* chronic) and mechanism (hematogenous *versus* contiguous, with or without vascular compromise), whereas the Cierny-Mader system further accounts for anatomical involvement and host physiology [7]. Modern considerations also factor in temporal onset (acute <2 weeks; chronic >6 weeks), anatomical location, host vascular and immunologic status, and presence of implants [2,8].

When osteomyelitis is acute, it is characterized by systemic signs such as fever and malaise, local symptoms, such as pain and swelling, and lab markers such as elevated levels of inflammatory markers like C-reactive protein and erythrocyte sedimentation rate [8]. Chronic cases, on the other hand, often present indolently, with draining sinuses and persistent pain [2,8]. Chronic osteomyelitis occasionally presents with pathological fractures and often without systemic symptoms, especially in compromised hosts or when hardware is present [2,8].

Diagnosis relies on the integration of clinical, laboratory, imaging, and microbiological evidence

Bone biopsy remains the gold standard for pathogen identification in osteomyelitis [2,8]. Notably, in chronic osteomyelitis with sinus tracts, two consecutive deep sinus tract cultures (with bone contact) have a high predictive value for identifying the causative pathogen, showing 96 percent concordance with bone biopsy in monomicrobial cases [2,9].

In addition to bone biopsy, imaging can contribute to osteomyelitis diagnosis. For instance, Magnetic Resonance Imaging (MRI) excels at early detection due to its high sensitivity and specificity in soft tissue [10-12]. Nuclear medical approaches, such as leukocyte scans, Positron Emission Tomography (PET), and Computed Tomography (CT) provide additional specificity in complex cases, especially when infections arise from prosthetics [13,14].

There are certain special populations, who, upon diagnosis, may require certain considerations to optimize management. For example, pediatric patients with hematogenous spread and prevalent metaphyseal involvement should raise concerns regarding potential growth disturbances [2,8]. In addition, in diabetic foot, which is characterized by polymicrobial, contiguous spread in the presence of vascular disease and neuropathy, the "probe-to-bone" test remains highly predictive, and amputation is required in 15 to 25 percent of cases [2,15,16].

There are multiple treatment strategies, often involving antimicrobial therapy and surgical management

Antimicrobial therapy in osteomyelitis typically involves a long course of 6 to 12 weeks, adjusted based on culture data [17-19]. Antibiotic combinations chosen before the exact causative organism is known should cover likely pathogens, such as staphylococci, Methicillin Resistant *Staphylococcus Aureus* (MRSA), gram-negatives, and anaerobes [18,19]. MRSA-targeted options include vanomycin, with linezolid or daptomycin as alternatives. Gram-negative coverage may utilize fluoroquinolones because of their ability to penetrate bone [18,19].

Surgical management is indicated when sequestrum abscesses, hardware-associated infections, or spinal instability are present, when medical therapy has failed, and when there is involvement deemed limb-threatening [2,8,20]. Key surgical approaches include thorough debridement with removal of necrotic tissue and reconstruction strategies [20,21]. Debridement may require repetition [20]. The Masquelet or induced membrane technique, is an especially effective two-stage reconstructive approach for large bone defects, with success rates exceeding 75 percent in complex long-bone reconstructions. In deep-seated infections, repeated washouts are often required [21].

Adjunctive measures may provide value in intervention in osteomyelitis. Local antibiotic delivery systems with Polymethylmethacrylate (PMMA) cement spacers or beads impregnated with gentamicin or other agents can achieve high local concentrations, whereas hyperbaric oxygen therapy may augment healing in refractory cases with poor vascularity [19,21]. Imaging can also support intervention. Plain radiographs can be used to monitor progression but lack sensitivity in early disease. Due to its superior bony detail, CT is also useful for surgical planning or guiding biopsy [11,12].

In severe cases where infection cannot be controlled, particularly with extensive bone and soft-tissue loss, poor vascular supply, or multiple failed salvage attempts, amputation may become necessary [22-25]. Functional outcomes after amputation depend heavily on rehabilitation, prosthetic fitting, and patient comorbidities [22,26]. Delaying amputation in the setting of non-salvageable limbs can prolong morbidity, increase infection risk, and reduce quality of life [25].

An illustrative case underscores the complexity of managing post-traumatic osteomyelitis

Patient information: A 65-year-old, Caucasian, right-hand dominant male was seated on a metal bench in front of a restaurant shopping mall area when a car lost control and struck him, pinning him under the vehicle. He was unconscious at the scene, bleeding from his extremities and suffered multiple abrasions, lacerations and fractures. EMS found significant injuries to both upper and lower extremities, with left leg deformity and swelling. He was transported to a Level One trauma center.

Initial findings included: Open wounds and significant swelling in the left lower extremity. Loss of tissue, especially around the left knee and foot. Hypotension requiring transfusion of packed red blood cells. Extensive imaging revealing multi-system trauma.

Initial diagnostic findings: Neuroimaging revealed a nasal bone fracture and a small right-sided frontal subdural hemorrhage not requiring neurosurgical intervention. Orthopedic imaging showed multiple pelvic fractures involving the superior and inferior pubic rami with acetabular extension and sacral fracture, retained metallic fragments in the pelvis and leg and complex fractures of the left femur, tibia, fibula and ankle joint. Vascular

studies identified injury to the distal superficial femoral artery with pseudoaneurysm formation.

Initial surgical management

The patient underwent emergent irrigation and debridement of multiple Grade 3 open fractures. External fixation devices were applied to stabilize the femur and ankle. Vascular repair was performed for a peripheral artery injury in the lower extremity. Photos from the last surgeries are provided in the Supplemental Material (Figures 1-13).

Figure 1: Sinus tract on skin that adhered to bone.

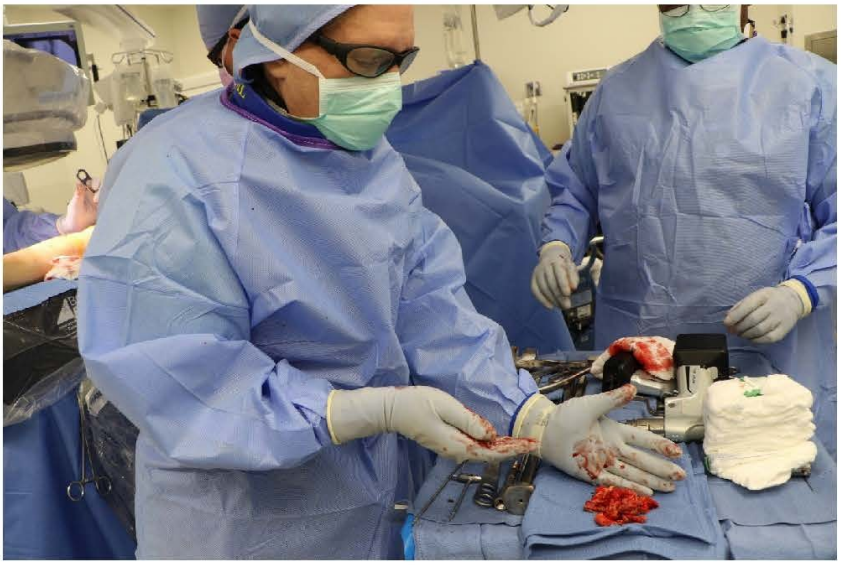

Figure 2: Necrotic infected bone that was removed.

Figure 3: Infected bone.

Figure 4: Infected bone marrow.

Figure 5: Debridement of intermedullary canal with Remur Irrigator Aspirator (RIA).

Figure 6: Remur irrigator aspirator being placed.

Figure 7: Copious irrigation of the infected bone.

Figure 8: Irrigation with antimicrobial fluid.

Figure 9: Replacement of new retrograde nail.

Figure 10: Placement of distal locking screws.bone.

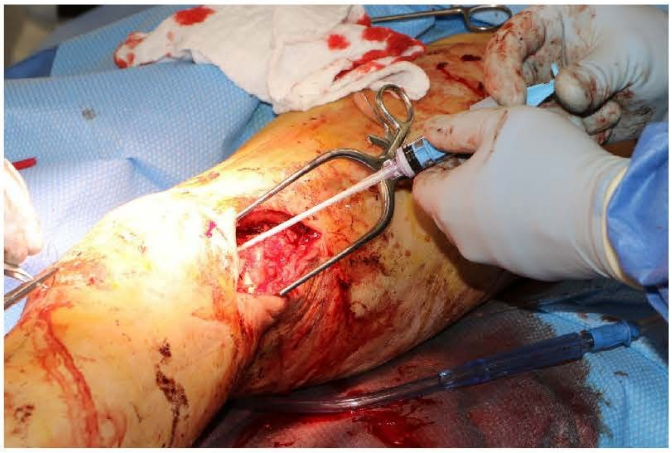

Figure 11: Application of Cerament G (Composite of calcium sulfate, calcium hydroxyapatite, and gentamicin).

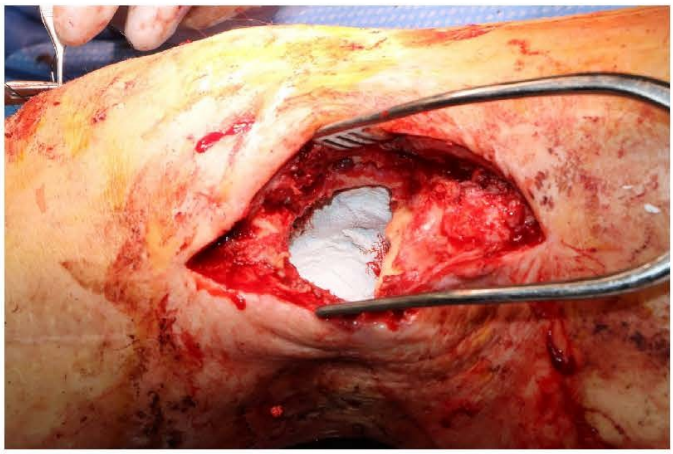

Figure 12: Fully crystallized Ceramen t G.

Figure 13: Soft tissue coverage complete with thigh advancement and gastrocnemius flap.

Subsequent surgeries and procedures

Over the following weeks, he required repeated debridements and wound washouts, as well as additional orthopedic procedures, including retrograde intramedullary nailing of the femoral shaft and open reduction internal fixation of a lateral condyle fracture.

Persistent infection complicated recovery, with cultures positive for methicillin-sensitive *Staphylococcus aureus* and Pseudomonas. This necessitated prolonged intravenous antibiotics, eventual removal of orthopedic hardware, placement of antibiotic cement spacers and bone graft substitutes. Hyperbaric oxygen therapy was initiated to support wound healing, but recurrent wound breakdown at the left knee required multiple further surgical interventions.

Rehabilitation and recovery

Rehabilitation began with an acute inpatient rehabilitation program addressing impaired gait, balance and activities of daily living. He transitioned to an outpatient physical medicine program under close medical supervision by a physiatrist. Due to functional limitations, he required home health aide services eight hours per day, seven days a week for mobility assistance (including fall prevention), wound care and daily living needs.

Ongoing complications

The patient experienced chronic pain in his left knee, ankle and foot, which he frequently rated at 8 to 10 on a 10 point pain scale, along with numbness, tingling and weakness in his left lower extremity. MRI with diffusion tensor imaging confirmed a moderate traumatic brain injury and he reported persistent memory and concentration difficulties. Due to the severity of his injuries and recurrent infections, he remained at risk for an above-knee amputation.

Current status and prognosis

At the most recent follow-up, the patient remained under the care of a multidisciplinary care team, including orthopedic surgery, plastic surgery, vascular surgery, infectious disease, neurology and physiatry. He continued to require daily assistance, had limited weight-bearing ability and required ongoing wound monitoring. His prognosis remained guarded due to the persistent infection risk, chronic pain, neurocognitive symptoms and functional limitations

CONCLUSION

This case highlights the challenges of treating deep-seated post-traumatic osteomyelitis involving multiple long bones and polymicrobial infection, including Gram-negative organisms. Repeated surgical debridement, targeted antimicrobial therapy and local antibiotic delivery were all critical in achieving infection control. Management was complicated by the biology of chronic bone infection. Poor local vascularity, biofilm formation and sequestra that acted as bacterial reservoirs. Removal of hardware, while destabilizing in the short term was essential to eradication.

The case also underscores the importance of early aggressive surgical management in severe open fractures to prevent chronic infection. In situations where salvage is unlikely to result in a functional limb, early amputation should be discussed as part of shared decision making to reduce prolonged morbidity.

Optimal management requires early intervention, multidisciplinary coordination and individualized treatment planning. Deep-seated post-traumatic osteomyelitis represents one of the most challenging conditions in musculoskeletal infection management, combining the inherent difficulties of chronic bone infection with the added complexity of high-energy trauma, vascular compromise and potential hardware involvement. Across the literature the consensus emphasizes early and thorough surgical debridement, culture-directed prolonged antimicrobial therapy and adjunctive measures such as local antibiotic delivery and hyperbaric oxygen therapy when appropriate. Equally important is timely recognition of when salvage is no longer viable, with early consideration of amputation in non-functional or high-morbidity limbs. Multidisciplinary coordination and individualized treatment planning remain essential to achieving infection control, preserving function, and optimizing patient outcomes.

REFERENCES

1. Fa W. Osteomyelitis: A review of clinical features, therapeutic considerations, and unusual aspects. N Engl J Med. 1970;282:316-322.
2. Lew DP, Waldvogel FA. Osteomyelitis. The Lancet. 2004;364(9431):369-379.
3. Lipsky BA, Berendt AR, Cornia PB, Pile JC, Peters EJ, Armstrong DG, et al. 2012 Infectious Diseases Society of America clinical practice guideline for the diagnosis and treatment of diabetic foot infections. Clin Infect Dis. 2012;54(12):132-173.
4. Brady RA, Leid JG, Calhoun JH, Costerton JW, Shirtliff ME. Osteomyelitis and the role of biofilms in chronic infection. FEMS Immunol Med Microbiol. 2008;52(1):13-22.
5. Kremers HM, Nwojo ME, Ransom JE, Wood-Wentz CM, Melton III LJ, Huddleston III PM. Trends in the epidemiology of osteomyelitis: A population-based study, 1969 to 2009. J Bone Joint Surg Am. 2015;97(10):837-845.
6. Zimmerli W, Trampuz A, Ochsner PE. Prosthetic-joint infections. N Engl J Med. 2004;351(16):1645-1654.
7. CIERNY GI. A clinical staging system for adult osteomyelitis. Contemp Orthop. 1985;10:17-37.
8. Hatzenbuehler J, Pulling TJ. Diagnosis and management of osteomyelitis. American family physician. 2011;84(9):1027-1033.
9. Mader JT, Shirtliff ME, Bergquist SC, Calhoun J. Antimicrobial treatment of chronic osteomyelitis. Clin Orthop Relat Res. 1999;360:47-65.
10. Kaim AH, Mueller GM, Raduechel R, et al. MR imaging and CT in osteomyelitis of the foot in patients with diabetes mellitus. Eur Radiol. 2002;12(5):1001-1007.
11. Pineda C, Espinosa R, Pena A. Radiographic imaging in osteomyelitis: The role of plain radiography, computed tomography, ultrasonography, magnetic resonance imaging, and scintigraphy. Semin Plast Surg. 2009;23(2):80-89.
12. Termaat MF, Raijmakers PG, Scholten HJ, Bakker FC, Patka P, Haarman HJ. The accuracy of diagnostic imaging for the assessment of chronic osteomyelitis: A systematic review and meta-analysis. J Bone Joint Surg Am. 2005;87(11):2464-2471.
13. Glaudemans AW, Jutte PC, Cataldo MA, Cassar-Pullicino V, Gheysens O, Borens O, et al. Consensus document for the diagnosis of peripheral bone infection in adults: a joint paper by the EANM, EBJIS, and ESR (with ESCMID endorsement). Eur J

Nucl Med Mol Imaging. 2019;46(4):957-970.

14. Kwee TC, Kwee RM, Alavi A. FDG-PET/CT in diagnosing musculoskeletal infection: A systematic review and meta-analysis. Eur J Nucl Med Mol Imaging. 2008;35(6):1122-1132.
15. Lavery LA, Armstrong DG, Wunderlich RP, Mohler MJ, Wendel CS, Lipsky BA. Risk factors for foot infections in individuals with diabetes. Diabetes care. 2006;29(6):1288-1293.
16. Lipsky BA, Aragon-Sanchez J, Diggle M, Embil J, Kono S, Lavery L, et al. IWGDF guidance on the diagnosis and management of foot infections in persons with diabetes. Diabetes Metab Res Rev. 2016;32:45-74.
17. Spellberg B, Lipsky BA. Systemic antibiotic therapy for chronic osteomyelitis in adults. Clin Infect Dis. 2012;54(3):393-407.
18. Conterno LO, da Silva Filho CR. Antibiotics for treating chronic osteomyelitis in adults. Cochrane Database Syst Rev. 2009(3):4439.
19. Mader JT, Shirtliff ME, Bergquist SC, Calhoun J. Antimicrobial treatment of chronic osteomyelitis. Clin Orthop Relat Res. 1999;360:47-65.
20. Penn-Barwell JG, Murray CK, Wenke JC. Early antibiotics and debridement independently reduce infection in an open fracture model. J Bone Joint Surg Br. 2012;94(1):107-112.
21. Fitzgerald Jr RH, Ruttle PE, Arnold PG, Kelly PJ, Irons GB. Local muscle flaps in the treatment of chronic osteomyelitis. JBJS. 1985;67(2):175-185.
22. Thorud JC, Plemmons B, Buckley CJ, Shibuya N, Jupiter DC. Mortality after nontraumatic major amputation among patients with diabetes and peripheral vascular disease: A systematic review. J Foot Ankle Surg. 2016;55(3):591-599.
23. Wrobel JS, Mayfield JA, Reiber GE. Geographic variation of lower-extremity major amputation in individuals with and without diabetes in the Medicare population. Diabetes care. 2001;24(5):860-864.
24. Van Battum P, Schaper N, Prompers L, Apelqvist J, Jude E, Piaggesi A, et al. Differences in minor amputation rate in diabetic foot disease throughout Europe are in part explained by differences in disease severity at presentation. Diabet Med. 2011;28(2):199-205.
25. Armstrong DG, Wrobel J, Robbins JM. Guest editorial: Are diabetes-related wounds and amputations worse than cancer? Int Wound J. 2007;4(4):286-287.
26. Murdoch DP, Armstrong DG, Dacus JB, Laughlin TJ, Morgan CB, Lavery LA. The natural history of great toe amputations. J Foot Ankle Surg. 1997;36(3):204-208.

Physiatrist's Voice
NEWSLETTER December 2025

Osteomyelitis

By Craig Lichtblau, M.D.

Introduction

Osteomyelitis (bone infection) is either an acute or chronic inflammatory process involving the bone and its structures, secondary to infection with pyogenic organisms, including bacteria, fungi, and mycobacteria. There have been archaeological finds showing animal fossils with evidence of bone infection, making this an old disease.

Before the introduction of penicillin in the 1940s, management of osteomyelitis was mainly surgical consisting of extensive debridement and wound packing with the affected area being left to heal by secondary intention resulting in a high mortality rate from sepsis. Since the availability of antibiotics, mortality rates from osteomyelitis, including staphylococcal osteomyelitis, have improved significantly.

Etiology

Healthy intact bone is resistant to infection. The bone becomes susceptible to disease with the introduction of a large inoculum of bacteria, trauma, ischemia, or the presence of foreign bodies because bone sites to which microorganisms can bind to are exposed.

Certain bacteria such as *Staphylococcus aureus* adhere to the bone by expressing receptors, called adhesins, for some components of the bone matrix, including laminin, collagen, fibronectin, and bone sialoglycoprotein. *S. aureus* expresses a collagen-binding adhesin, which permits its attachment to bone cartilage while the fibronectin-binding adhesin's role in attachment of bacteria to surgically implanted devices in bone was recently discovered.

Some bacteria create a protective biofilm coating around themselves and underlying surfaces. This characteristic of some bacteria to adhere to the bone and surgically implanted devices as well as express phenotypic resistance to antibiotic therapy and survive intracellularly may explain the persistence of bone infections and the high failure rates of shorter courses of antimicrobial treatment.

Pathophysiology

Bone can get infected via a hematogenous route of infection through bacteremic seeding of bone from a distant source of infection, contiguous spread from surrounding tissue and joints, or direct inoculation of bone from trauma or surgery. Hematogenous osteomyelitis occurs more

Osteomyelitis
by Craig H. Lichtblau, M.D.
-continued-

frequently in children compared to adults, and the long bones are usually affected. In adults, hematogenous osteomyelitis affects the vertebrae most commonly. Contiguous osteomyelitis in young adults usually occurs in the setting of trauma and related surgery, while in older adults, infection is typically related to decubitus ulcers and infected joint arthroplasties. Osteomyelitis associated with vascular insufficiency frequently occurs in the presence of underlying diabetes mellitus.

In patients with diabetes, osteomyelitis usually results from compromised blood supply to the lower extremities, which contributes to impaired local immunity and skin healing, promoting the spread of infection. Sensory neuropathy, in the setting of diabetes mellitus, predisposes the body to the formation of skin ulceration at pressure and trauma points, complicating matters even worse.

Contiguous osteomyelitis frequently develops in debilitated patients who are wheelchair or bedbound and are predisposed to pressure-related skin ulcerations, especially in the sacrum, buttock, hips, and heel. The ulcers are typically colonized by polymicrobial flora from the skin and gastrointestinal tract such that soft tissue infection can quickly spread to the underlying bone. Other sources of contiguous osteomyelitis are trauma leading to infected, exposed skin and soft tissue. Osteomyelitis with direct inoculation of bacteria may occur in the setting of open fractures, bone reconstructive surgery, or with placing orthopedic hardware.

Histopathology

The well-perfused metaphyses, which have scarce functioning phagocytes, are the most common site of infection in hematogenous osteomyelitis affecting the long bones. The blood supply to the long bones penetrates the bone at the mid-shaft and then splits into two which travels to both metaphyseal endplates. Slowing of blood flow in vascular loops at the metaphysis encourages the deposition of microbes and the establishment of infection.

To contain the disease, phagocytes release enzymes that lyse bone, creating an inflammatory response. This inflammatory response forms pus, a protein-rich exudate containing dead phagocytes, tissue debris, and microorganisms, and causes increased intramedullary pressure. The inflammatory exudate can rupture through the cortex to the periosteum if left unchecked. Disruption of the periosteum impairs the periosteal blood supply leading to bone ischemia then necrosis.

Separated pieces of necrotic bone are called sequestra, which occasionally contain pus. New bone formation over the injured periosteum is called involucrum, and it may partially surround a sequestrum. Discharge from a sequestrum can lead to sinus tract formation.

Physiatrist's Voice
NEWSLETTER December 2025

Osteomyelitis
by Craig H. Lichtblau, M.D.
-continued-

The main histopathological finding in acute osteomyelitis are microorganisms, congested or thrombosed blood vessels, and infiltrates of neutrophils. The hallmark histopathological finding in chronic osteomyelitis is necrotic bone. Other features of chronic osteomyelitis include the predominance of mononuclear cells, replacement of osteoclast resorbed bone by granulation, and fibrous tissue leading to bone loss and the formation of sinus tracts, which are pathognomonic.

Evaluation

Laboratory data can be useful in the assessment of osteomyelitis but are usually nonspecific for osteomyelitis. There may or may not be leukocytosis, the elevation of ESR, and C-reactive protein (CRP).

The CRP level correlates with clinical response to therapy and may be used to monitor treatment. Blood cultures may be positive, especially in hematogenous osteomyelitis involving the vertebrae, clavicle, or pubis.

Radiographic imaging is an essential component of the evaluation of a patient with suspected osteomyelitis. Clinically, the most useful studies are plain radiographs, magnetic resonance imaging (MRI), and technetium-99 bone scintigraphy.

A plain radiograph is usually the initial imaging of choice but may have a delay of about 14 days before the appearance of findings suggestive of osteomyelitis. They are used to rule out other potential causes of symptoms such as metastasis or osteoporotic fractures. Typically seen are soft tissue swelling, osteopenia, osteolysis, bony destruction, and nonspecific periosteal reaction. Lytic lesions are detectable on plain radiographs after approximately 50% to 75% of the bone matrix has been lost, making this modality inadequate for the detection of early bone disease.

Of all the imaging modalities currently in use, MRI has the highest combined sensitivity and specificity for detecting osteomyelitis. It can detect early bone infection within 3 to 5 days of disease onset, but its use is limited in the setting of surgical hardware. MRI has a high negative predictive value, so a negative result is sufficient for the exclusion of disease if symptoms have been present for at least one week. The use of intravenous contrast does not improve the detection of disease but helps provide the distinction between a phlegmon, necrotic tissue, and abscess.

Nuclear imaging has a high sensitivity for detecting early evidence of bone disease but has very poor specificity. It is especially useful if metal hardware prevents the use of MRI. Three-phase technetium-99 bone scan and tagged white blood cell scans are the modalities commonly used.

Osteomyelitis
by Craig H. Lichtblau, M.D.
-continued-

Bone biopsy, either open or percutaneously, is essential to establish the histopathological diagnosis in osteomyelitis, identify the causative pathogen, and provide susceptibility data that helps direct antibiotic therapy. Superficial wound cultures or material from needle puncture or sinus tracts should not be used in diagnosis as these specimens do not correlate well with bone biopsy results. In patients with positive blood cultures and radiographic evidence of osteomyelitis, a bone biopsy may not be very useful. An open bone biopsy is preferred over percutaneous biopsy, if possible.

Cessation of antibiotics 48 to 72 hours before open bone biopsy may increase microbiological yield but is not routinely necessary as bone cultures are often positive regardless of prior antibiotic therapy because these infections occur in areas of infection-induced infarction or necrosis. Percutaneous biopsy should be done through intact skin to prevent sampling errors, and fluoroscopic or CT guidance is preferable. Percutaneous biopsy should be done ideally before initiation of antibiotic therapy, if possible, to increase the microbiological yield. Usually recommended is the collection of 2 samples, one for histopathology and the other for culture and gram stain.

Treatment

Hematogenous osteomyelitis is primarily monomicrobial, while osteomyelitis due to contiguous spread or direct inoculation is usually polymicrobial or monomicrobial. The most common pathogens in osteomyelitis depend on the patient's age. *Staphylococcus aureus* is the most common cause of acute and chronic hematogenous osteomyelitis in adults and children.

Effective treatment of osteomyelitis involves a collaborative effort among various medical and surgical specialties. The two main aspects of therapy are surgical containment of the infection and prolonged antibiotics. Surgical debridement of all diseased bone is often required as antibiotics penetrate poorly into infected fluid collections such as abscesses and injured or necrotic bone. Thus, the removal of necrotic tissue and bone is usually indicated where feasible.

In osteomyelitis associated with prosthetic joints, removal of the hardware is indicated. However, if the infected prosthesis is in a stable joint such as the hip and is infected with a very susceptible organism such as streptococci, therapy with an extended antibiotic course for several months without removing the device has been successful. When the prosthesis has to be removed, a two-stage exchange arthroplasty is more commonly used as this carries less risk of recurrent infection compared to the 1-stage arthroplasty, especially if more virulent bacteria such as *S. aureus* is involved. If surgical debridement is not feasible based on the location of the infection, such as some cases of pelvic osteomyelitis, then extended antibiotic therapy for months may be used.

The need for revascularization of an affected limb is important before surgical intervention if there is evidence of significant peripheral vascular disease, control diabetes mellitus, and address

Osteomyelitis
by Craig H. Lichtblau, M.D.
-continued-

other host factors that may impede wound healing such as tobacco use, malnutrition, chronic hypoxia, immunodeficiency states, chronic lymphedema and peripheral neuropathy.

Prolonged antibiotic therapy is the cornerstone of treatment for osteomyelitis. Results of culture and sensitivity should guide antibiotic treatment if possible, but in the absence of this data, it is reasonable to start empiric antibiotics. A commonly used broad-spectrum empiric antibiotic regimen against both gram-positive and negative organisms, including MRSA, is vancomycin (15 mg/kg intravenously [IV] every 12 hours) plus a third a generation cephalosporin (ceftriaxone 2 gram IV daily) or a beta-lactam/beta-lactamase inhibitor combination (piperacillin/tazobactam 3 gram - 0.375 gram IV every 8 hours). Once sensitivity data becomes available, then the antibiotic therapy should be narrowed for targeted coverage of the susceptible organisms.

The recommended duration of treatment for osteomyelitis in adults is 4 to 6 weeks of parenteral antibiotic therapy to achieve acceptable cure rates with a decreased risk of recurrence.

Prognosis

With aggressive early treatment, the prognosis of acute osteomyelitis is good. However, there is a possibility that the infection could recur years after successful treatment if there is new trauma to the same area or if host immunity is compromised.

In adults, the recurrence rate of chronic osteomyelitis is about 30% at 12 months, but in cases involving P. aeruginosa, the recurrence rate may be as high as 50%. Cases involving prosthetic devices are more difficult to treat, causing increased morbidity due to the need for more surgical procedures and extended antibiotic courses required for treatment.

Recommended also is the use of prophylactic preoperative antibiotic treatment administered parenterally 30 minutes before skin incision with first-generation (cefazolin) or second-generation cephalosporins (cefuroxime). All these measures have been shown to decrease the rate of postoperative infections from 0.5% to 2%, thereby improving patient outcomes.

Physiatrist's Voice
NEWSLETTER December 2025

Osteomyelitis
by Craig H. Lichtblau, M.D.
-continued-

Complications

Septic arthritis.
Pathological fractures.
Squamous cell carcinoma.
Sinus tract formation.
Amyloidosis (rare).
Abscess.
Bone deformity.
Systemic infection.
Contiguous soft tissue infection.

Recommendations

A strong collaboration between the surgical and vascular teams is essential for the effective management of osteomyelitis due to vascular insufficiency, especially if associated with diabetes mellitus. Revascularization of the affected limb is critical for proper wound healing. Procedures to restore adequate blood flow, including therapeutic angiogram by either interventional radiology or vascular surgery and even femoral to popliteal bypass, are used before amputation depending on the severity of vascular insufficiency. Surgical revascularization procedures that use local pedicle muscle flaps and myocutaneous flaps maintain vascular supply to the surgical site, fill the space left by surgical debridement, and also fight infection.

Physiatrist's Voice
NEWSLETTER December 2025

Osteomyelitis
by Craig H. Lichtblau, M.D.
-continued-

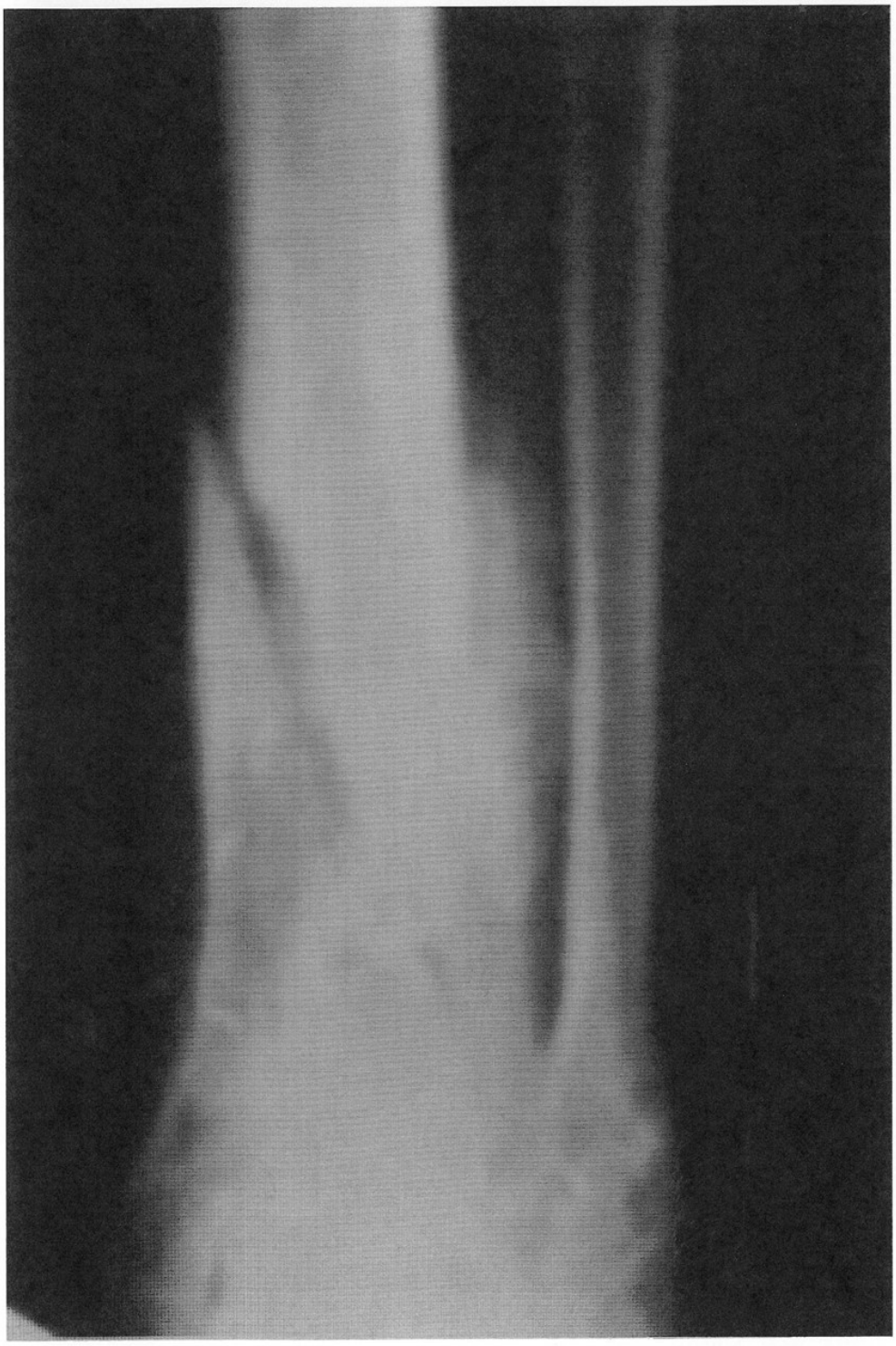

Physiatrist's Voice
NEWSLETTER December 2025

Osteomyelitis
by Craig H. Lichtblau, M.D.
-continued-

Physiatrist's Voice
NEWSLETTER December 2025

Blood Flow Restriction Training in Sports Rehabilitation

Maximizing muscle recovery while protecting healing tissue in post-surgical athletes

Introduction



Clayton Moss, MD
PGY3, USF PM&R

Blood flow restriction (BFR) training has emerged as a powerful tool in sports medicine rehabilitation, allowing PM&R physicians to stimulate hypertrophy and strength gains while respecting surgical repairs and healing timelines. By pairing low-load exercise (20-30% of 1RM) with strategic vascular occlusion, BFR creates a metabolic environment similar to high-load training, without the mechanical stress that can compromise post-surgical outcomes.

The Science Behind BFR

BFR addresses a critical rehabilitation challenge: preventing the rapid muscle atrophy that occurs during periods of restricted loading. The physiological mechanisms are well-established and clinically significant.

BFR training produces documented effects including fast-twitch fiber recruitment under hypoxic conditions[1], enhanced anabolic signaling through growth hormone and IGF-1 pathways[2□3], and elevated metabolic stress with lactate accumulation exceeding standard low-load training[4]. These mechanisms explain why BFR produces hypertrophy and strength outcomes closely mirroring heavy resistance training, which is a critical advantage for injured athletes who cannot tolerate high mechanical loads.

Evidence in Post-Surgical Rehabilitation

ACL Reconstruction

Quadriceps atrophy remains one of the strongest contributors to delayed return-to-sport and reinjury risk. A 2024 systematic review demonstrated that BFR meaningfully improved quadriceps strength, enhanced IKDC and Lysholm functional scores, and preserved thigh muscle mass more effectively than standard rehabilitation alone[5].

Physiatrist's Voice
NEWSLETTER December 2025

Blood Flow Restriction Training in Sports Rehabilitation

Maximizing muscle recovery while protecting healing tissue in post-surgical athletes

- continued—

Meniscus Repair

Weight-bearing restrictions following meniscus repair often trigger rapid quadriceps decline. Recent evidence shows early low-load BFR preserved quadriceps size post-meniscus repair without increasing surgical risk, supporting its integration during restricted loading phases[6].

Performance Applications

A 2024 meta-analysis of 28 athletic studies revealed BFR improves strength, sprint performance, muscular endurance, and lean mass[7]. Because BFR uses low loads, it reduces joint stress and graft strain, making it ideal for in-season maintenance, pain-limited athletes, deload phases, and return-to-sport progressions. It represents one of the few tools allowing athletes to meaningfully stimulate. muscle without the mechanical cost of heavy lifting.

Special Populations

Athletes with chronic joint pain or early osteoarthritis who struggle with heavy loading benefit significantly from BFR. Research demonstrates BFR produces hypertrophy and strength gains comparable to high-load resistance training in knee osteoarthritis populations[8]. Additionally, older athletes with sarcopenia showed significant improvements in strength, gait speed, and muscle quality after BFR training[9], making it valuable for aging competitors or those with chronic load intolerance.

Safety Profile

The safety data for BFR is robust when individualized pressures and wide cuffs are utilized. In a cohort of 12,642 BFR users, deep vein thrombosis occurred in only 0.055% and pulmonary embolism in 0.008%[10]. BFR does not activate coagulation pathways beyond normal training[11], and rhabdomyolysis and nerve injury rates mirror conventional resistance training when proper technique is employed[12].

Physiatrist's Voice
NEWSLETTER December 2025

Blood Flow Restriction Training in Sports Rehabilitation

Maximizing muscle recovery while protecting healing tissue in post-surgical athletes

- continued—

Key contraindications include DVT/PE history, peripheral vascular disease, uncontrolled hypertension, sickle cell disease, and anticoagulant therapy.

Best-practice parameters: 40-80% limb occlusion pressure, 2-4 sets of 15-30 reps, wide pneumatic cuffs, and supervised progression.

Clinical Takeaway

BFR training represents an evidence-based addition to a sports medicine practice. Its ability to stimulate hypertrophy with minimal mechanical load makes it particularly valuable for post-surgical athletes, in-season maintenance, older athletes managing osteoarthritis, and athletes requiring performance preservation during recovery. By understanding proper application and contraindications, PM&R physicians can leverage BFR to maximize recovery, protect healing tissue, and accelerate safe return-to-sport.

References

Jessee, M. B., et al. (2018). Fast-twitch fiber recruitment under BFR conditions.
Fujita, S., et al. (2007). Enhanced anabolic signaling with BFR training.
Pearson, S. J., & Hussain, S. R. (2015). mTORC1 activation during BFR.
Suga, T., et al. (2012). Metabolic stress and lactate accumulation in BFR training.
Butt, U., et al. (2024). BFR effectiveness in ACL reconstruction rehabilitation: A systematic review.
Yamanashi, A., et al. (2024). Early BFR preservation of quadriceps post-meniscus repair.
Yang, X., et al. (2024). Meta-analysis of BFR effects on athletic performance.
Ferlito, J. V., et al. (2020). BFR training in knee osteoarthritis populations.
Jing, D., et al. (2025). BFR training effects in older athletes with sarcopenia.
Nakajima, T., et al. (2016). Safety profile of BFR training: Large cohort analysis.
Bond, C. W., et al. (2022). Coagulation pathway activation during BFR training.
Miller, B. C., et al. (2021). Adverse event rates in BFR versus conventional training.

Physiatrist's Voice
NEWSLETTER December 2025

Residency Updates

- UMiami
- Memorial Health
- Broward Health
- UCF/HCA FL West Hospital
- UFlorida
- Larkin Community Hospital

Physiatrist's Voice
NEWSLETTER December 2025

University of Miami Miller School of Medicine/Jackson Memorial Hospital PM&R Residency Update
Dylan Wood, Resident Liaison
Diana Molinares MD, PM&R Residency Program Director

University Miami FSPMR
December 2025 Edition

FSPM&R,

As we near the end of another successful year, our department continues to grow, achieve, and inspire. From national conference presentations to remarkable individual accomplishments, our community exemplifies the energy,
dedication, and collaboration that define the field of Physical Medicine and Rehabilitation.

We had a fantastic showing at the AAPM&R Annual Assembly this year! Our residents represented the University of Miami with excellence—delivering podium presentations, presenting posters, and connecting with enthusiastic medical students at our booth. It was energizing to see so many future physicians interested in PM&R and to share in their
excitement for the specialty.

We are proud to celebrate several outstanding achievements within our department:

- Dr. Mark Williams successfully matched into the Pain Medicine Fellowship at UCLA—a tremendous milestone and testament to his dedication and clinical skill.

- Dr. Dianna Molinares, our Program Director, has been appointed Chair of Cancer Rehabilitation for AAPM&R, a prestigious recognition of his leadership and contributions to the field.

- Dr. Felicia Watson continues to inspire us with her athletic excellence—completing both a Half Ironman and
  placing 1st in a Full Ironman. She has qualified for both the half iron man and full iron man world championships this summer. Her commitment to both medicine and physical performance is truly remarkable.

Our residents also had the exciting opportunity to help provide medical coverage for the New York City Marathon, gaining invaluable hands-on experience in sports and event medicine while supporting thousands of athletes during one of the world's premier endurance events.

Physiatrist's Voice
NEWSLETTER December 2025

University of Miami Miller School of Medicine/Jackson Memorial Hospital PM&R Residency Update

Dylan Wood, Resident Liaison
Diana Molinares MD, PM&R Residency Program Director

- continued -

In keeping with our commitment to resident wellness and camaraderie, the team came together outside the hospital for a fun evening at a Miami Marlins game—a great reminder of the importance of balance and connection beyond clinical training.

Our department also continues to embrace Lifestyle Medicine and wellness, recently coming together for a whole-food, plant-based potluck lunch that highlighted both community and healthy living.

Looking ahead, we're preparing for a strong presence at the upcoming AAP Conference in Puerto Rico, where over 20 abstracts from our team have been accepted for presentation. We're excited to continue showcasing the University of Miami's dedication to advancing research, education, and excellence in PM&R.

Dr. Christian Diaz, Azmeer Khamisani, Dylan Wood, Sean Goldman, and Alec Cristian working with Dr. Davenport to assist in the Wellness Day for Performing Arts at HSS in West Palm Beach

Physiatrist's Voice
NEWSLETTER December 2025

University of Miami Miller School of Medicine/Jackson Memorial Hospital PM&R Residency Update

Dylan Wood, Resident Liaison
Diana Molinares MD, PM&R Residency Program Director

- continued -

Dr. Felicia Watson crossing the finish line to become an Ironman and qualify for Worlds

Physiatrist's Voice
NEWSLETTER December 2025

University of Miami Miller School of Medicine/Jackson Memorial Hospital PM&R Residency Update

Dylan Wood, , Resident Liaison
Diana Molinares MD, PM&R Residency Program Director

- continued -

Dr. Dylan Wood, Christian Diaz, Azmeer Khamisani, and Dr. Timothy Tiu volunteering for the medical staff for the NYC Marathon

University of Miami Miller School of Medicine/Jackson Memorial Hospital PM&R Residency Update

Dylan Wood, , Resident Liaison

Diana Molinares MD, PM&R Residency Program Director

- continued -

Large presence of residents, attendings, and staff at AAPM&R in Utah

Physiatrist's Voice
NEWSLETTER December 2025

University of Miami Miller School of Medicine/Jackson Memorial Hospital PM&R Residency Update

Dylan Wood , Resident Liaison
Diana Molinares MD, PM&R Residency Program Director

Faculty and Residents enjoying a Florida Marlins game

Physiatrist's Voice
NEWSLETTER December 2025

Memorial Healthcare System PM&R Residency Program

PM&R Resident Liaison Dev Patel MD
Jeremy Jacobs DO, Residency Program Director

- continued -

Dev Patel MD

Hello FSPM&R family!

We hope everyone has been doing great as we wrap up the year! We're excited to share some fun updates from the past few months in our December Newsletter.

To kick things off, our incredible musculoskeletal pathology expert, Dr. David Valdes, launched his new ultrasound workshop in October. The first session covered key anatomical landmarks of the wrist and their clinical correlations, with live ultrasound demonstrations highlighting proper technique and positioning. After an engaging hour-long lecture, residents split into small groups, where senior residents guided juniors through hands-on practice. The second session built on this foundation, focusing on the elbow.

Dr. Valdes teaching elbow anatomy to the residents

Physiatrist's Voice
NEWSLETTER December 2025

Memorial Healthcare System PM&R Residency Program

PM&R Resident Liaison Dev Patel MD
Jeremy Jacobs DO, Residency Program Director

- continued -

Under the leadership of our pain management specialist, Dr. Reed Yaras, we launched an exciting new resident-led educational initiative — the "Spine and Shine" course, a spine and fluoroscopy bootcamp designed for PM&R residents. This program aims to help residents build hands-on experience while developing confidence and competence in interventional spinal procedures. The bootcamp focuses on mastering foundational spine intervention skills through a mix of didactic sessions, live demonstrations, and structured practice. This ensures that residents entering pain, spine, sports, or MSK rotations can actively participate in procedures from day one. Each session wraps up with a procedure challenge — a timed, fluoroscopy-guided simulation that encourages teamwork, precision, and performance under pressure.

Dr. Reed Yaras (far left), one of our interventional pain specialists leading future aspiring pain doctors in the Spine and Shine course.

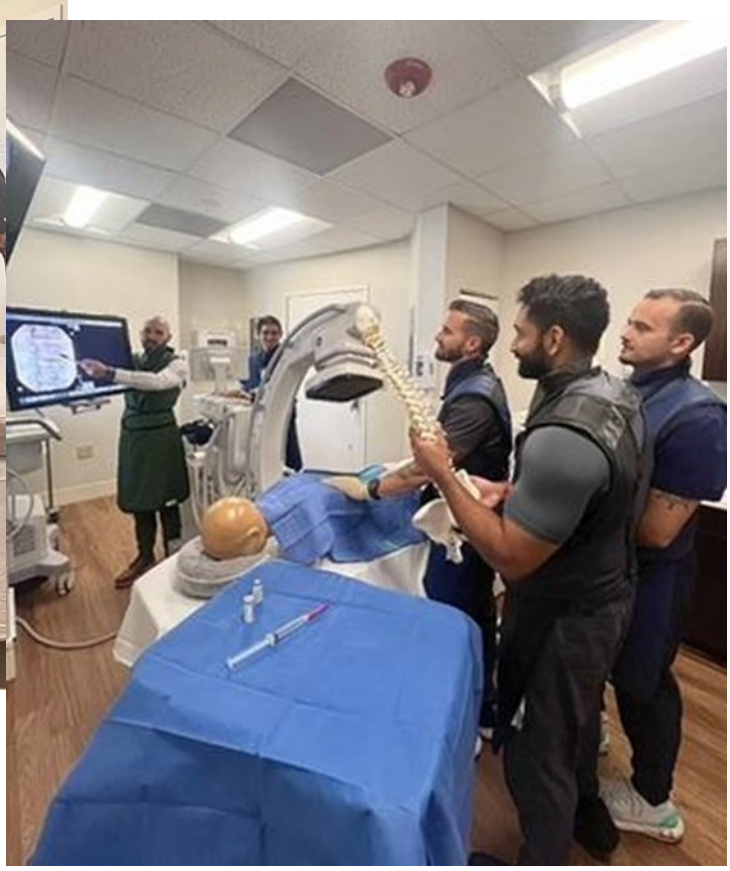

Memorial Healthcare System

Physiatrist's Voice
NEWSLETTER December 2025

Memorial Healthcare System PM&R Residency Program

PM&R Resident Liaison Dev Patel MD
Jeremy Jacobs DO, Residency Program Director
- continued -

Our residents and faculty had an amazing time representing our program at the AAPM&R Annual Assembly in Utah! It was a fantastic opportunity to connect with colleagues from across the country, share innovative ideas, and celebrate all the incredible work being done in the field of Physical Medicine and Rehabilitation. We're especially proud of our team's scholarly contributions — featuring posters from our former chief, Dr. Whitney Oliveira (middle), who is now practicing at UF Jacksonville, our current chief, Dr. Sri Moturu (left), and our outstanding PGY-3, Dr. Tahreem Hashmi (right). Their research and presentations reflected the dedication, curiosity, and collaborative spirit that make our program so special.

We're also thrilled to share that every single one of our residents was accepted to present at AAP in Puerto Rico! If you'll be attending, be sure to stop by and find us proudly standing next to our signature orange posters — we'd love to connect and share what our team has been working on!

Memorial Healthcare System

Physiatrist's Voice
NEWSLETTER December 2025

Memorial Healthcare System PM&R Residency Program

PM&R Resident Liaison Dev Patel MD
Jeremy Jacobs DO, Residency Program Director

- continued -

The Pain Management Fellowship Match Day happened this October, and we are excited to announce that our chief Dr. Cody Barbari (Pictured left) matched to his #1 choice at UT San Antonio!

Huge congratulations to Cody, we are so proud of you!

Memorial Healthcare System

Last but not least, we love to go all out in the Halloween spirit, check out these awesome and hilarious photos with our faculty and staff!

Physiatrist's Voice
NEWSLETTER December 2025

Memorial Healthcare System PM&R Residency Program

PM&R Resident Liaison Dev Patel MD
Jeremy Jacobs DO, Residency Program Director

- continued -

And that's a wrap to our program's updates for this quarter! More updates to come in the following months, especially with the AAP Conference in Puerto Rico this February. If you want to stay more up-to-date with our residency program's activities, follow our Instagram page below! As always, we wish that everyone has a wonderful Holiday season, a Happy New Year, and we look forward to hearing your updates and any exciting news!

@MHS_PMR_RESIDENCY

Physiatrist's Voice
NEWSLETTER December 2025

Broward Health PM&R Residency Update
Arian Khoshgowari DO , Resident Liaison
Meilani Mapa MD Residency Program Director
APD - Minh Quan Le

Greetings FSPM&R,

Arian Khoshgowari DO

It's been a very exciting time here at Broward Health's PM&R program and we're so excited to share our updates with you all. Every year, Broward Health holds a quality improvement competition among the different residency programs and fellowships across the hospital system known as Choosing Wisely. We're proud to have both of our quality improvement initiatives be accepted at national PM&R conferences, including AMRPA and AAPM&R. Now that the new academic year is in full swing, our residents are hard at work at trying to replicate the same success from last year, so stay tuned for more updates!

Pictured from Left to Right are Dr's: Kenneth Livingston (PGY3 General Surgery Resident), Keith Myers (PGY3), Melani Mapa (Program Director) presenting their
Choosing Wisely results at AMRPA in Philadelphia

Physiatrist's Voice

NEWSLETTER December 2025

Broward Health PM&R Residency Update
Arian Khoshgowari DO , Resident Liaison
Meilani Mapa MD Residency Program Director
APD - Minh Quan Le
- continued—

Arian Khoshgowari (PGY3) presenting his QI results at AAPM&R in Salt Lake City

Physiatrist's Voice
NEWSLETTER December 2025

Broward Health PM&R Residency Update
Arian Khoshgowari DO , Resident Liaison
Meilani Mapa MD Residency Program Director
APD - Minh Quan Le
- continued—

Pictured from Left to Right are Dr's: Quan Le (APD), Dan Harper (PGY3), Arian Khoshgowari (PGY3)

Drs. Dan Harper (PGY-3), Arian Khoshgowari (PGY-3), and Quan Le (APD) represented our program at the New York City Marathon, providing medical coverage at the finish line. It was an exciting opportunity to support runners recovering from the race and to apply their knowledge in managing acute musculoskeletal injuries.

Physiatrist's Voice
NEWSLETTER December 2025

Broward Health PM&R Residency Update
Arian Khoshgowari DO , Resident Liaison
Meilani Mapa MD Residency Program Director
APD - Minh Quan Le
- continued—

Dr's Arian Khoshgowari and Dan Harper celebrating their marathon sideline coverage with a selfie

Physiatrist's Voice
NEWSLETTER December 2025

Broward Health PM&R Residency Update
Arian Khoshgowari DO , Resident Liaison
Meilani Mapa MD Residency Program Director
APD - Minh Quan Le
- continued—

The residency program continues to advance its comprehensive ultrasound curriculum. In the session pictured below, residents practiced wrist ultrasound techniques and applied their knowledge to identify and correlate pathologic findings.

Our residents and visiting medical students practicing wrist ultrasound technique

Physiatrist's Voice
NEWSLETTER December 2025

Broward Health PM&R Residency Update
Arian Khoshgowari DO , Resident Liaison
Meilani Mapa MD Residency Program Director
APD - Minh Quan Le
- continued—

We've greatly enjoyed welcoming our new residents and seeing them bring their unique passions to the rehabilitation unit. Dr. Arian Khoshgowari has introduced *Focaccia Fridays*, a creative therapeutic activity where patients engage in the art of breadmaking and enjoy a delicious reward for their efforts.

Pictured below: Dr. Arian Khoshgowari (PGY3) turning in his stethoscope for a chef's hat at our inaugural Focaccia Friday in the ADL apartment.

As the holiday season approaches, our residents have eagerly joined in the festivities around the hospital. Following a rigorous prosthetics and orthotics didactic block, they brought their creativity to the annual Broward Health pumpkin carving contest, crafting a P&O-themed masterpiece

Physiatrist's Voice
NEWSLETTER December 2025

Broward Health PM&R Residency Update
Arian Khoshgowari DO , Resident Liaison
Meilani Mapa MD Residency Program Director
APD - Minh Quan Le
- continued—

We love celebrating birthdays here in our program! A very happy birthday to our Medical Director, Dr. Inocentes, we're grateful for your leadership, dedication, and the exceptional care you provide to our patients.

Pictured from Left to Right are Dr's: Arian Khoshgowari (PGY3), Jason Marcus (TY), Quan Le (APD), George Beshara (PGY2), JC Leach (PGY2), Ariel Inocentes (Medical Director), Francesca Inocentes (TY), Sophie Risi (PGY2), Carol Siu (PC), Elham Younesian (PGY2), David Yusupov (PGY2)

Broward Health PM&R Residency Update
Arian Khoshgowari DO , Resident Liaison
Meilani Mapa MD Residency Program Director
APD - Minh Quan Le
- continued—

Wellness remains a top priority for our residents! Next week, the team will be setting sail for a well-deserved wellness outing on the water. Stay tuned for photos and highlights from our boat day adventure! Until then, here is a photo of what we anticipate the day will look like

Physiatrist's Voice
NEWSLETTER December 2025

UCF/HCA/West FL Hospital PM&R Residency Program
Roberto Cordero, DO
Susan Belcher MD, Program Director
APD: Christopher Burton, MD

Roberto Cordero, DO

Hello from sunny Pensacola!

As we enter the holiday season, I'm grateful for Florida's warmth while much of the country cools down. With the academic year in full swing, our residents have been busy with scholarly activities, conferences, fitness, volunteering, and wellness initiatives. A big congratulations to our PGY-2s, who have completed their first three months of inpatient rehabilitation. We're very proud of how quickly they've adjusted, especially while learning our newly updated medical record system.

This fall, some of our residents attended the AAPM&R Annual Assembly. Two of our residents are also nearing completion of the Emerging Leaders in Spasticity Program (Phase 2 out of 3), showing strong commitment to advanced training. Our wellness events have been a highlight: A movie-premiere night hosted by one of our attendings Dr. Buchalter showcasing films written by another one of our talented attendings, Dr. Cahill, that touched on the genres of suspense-thriller. Many residents also participated in this year's AAP Fitness Challenge and stayed active through various events or hobbies that promoted wellness. Our chief resident completed a half-marathon.

We are also looking forward to our annual resident holiday celebrations, including our Friendsgiving and Secret Santa gift exchange, always a fun and meaningful way for our team to end the year together. We remain in the midst of interview season and are excited to meet all our candidates and welcome new residents this coming March. Additionally, we wanted to congratulate our attending Dr. Buchalter for winning the 2025 Golden Apple Award for Teaching Excellence with the UCFCOM! Finally, we proudly celebrate two of our PGY-4s who recently matched into Pain Medicine fellowships.

Wishing everyone a joyful and restful holiday season!

UCF College of Medicine | HCA Florida Healthcare

Physiatrist's Voice

NEWSLETTER December 2025

UCF/HCA/West FL Hospital PM&R Residency Program
Roberto Cordero, DO
Susan Belcher MD, Program Director
APD: Christopher Burton, MD

-continued -

Post-Match Spotlight

We are proud to present our matching seniors into the next chapter of their lives (Class of 2026):

Dr. Zachary Lin, PGY-4: Pain Fellowship at the University of Texas Medical Branch
Dr. Justin Buck, PGY-4: Pain Fellowship at the University of Florida College of Medicine

Their dedication, leadership, and compassion have left a lasting legacy on our program.

Curriculum & Training Highlights

Our curriculum continues to provide residents with diverse and innovative learning experiences through our didactics, simulation labs, journal clubs, and interdisciplinary grand rounds!

These experiences reflect our commitment to blending foundational learning with practical training to prepare residents for independent practice and fellowship readiness.



Lymphedema lecture
OT, Abigail presented

Journal Club
Dr. Ledbetter, Dr. Craig



Neck & Head Pain
Dr. Buchalter

Physiatrist's Voice
NEWSLETTER December 2025

UCF/HCA/West FL Hospital PM&R Residency Program
Roberto Cordero, DO
Susan Belcher MD, Program Director
APD: Christopher Burton, MD

-continued -



Interventional Pain
Dr. Meagher

Interdisciplinary Grand Rounds
Dr. Leung

Posttraumatic Seizures/
Epilepsy



Disorders of Consciousness
Dr. Cordero, Dekera Smith PharmD,
Dr. Romeo

Antioxidants in Brain injury
Dr. Hampton

UCF/HCA/West FL Hospital PM&R Residency Program
Roberto Cordero, DO
Susan Belcher MD, Program Director
APD: Christopher Burton, MD
-continued -

Academics + Research

We are incredibly proud of our PM&R residents whose scholarly work has been accepted for presentation at the upcoming AAP Annual Meeting in Puerto Rico. Their dedication to research, education, and advancing the field of rehabilitation medicine continues to elevate our program. We can't wait to cheer them on as they represent UCF/HCA PM&R in Puerto Rico!

This year, our residency program is excited to begin a new partnership with the Florida Institute for Human & Machine Cognition (IHMC), based in Pensacola. IHMC researchers are offering our residents opportunities to join ongoing projects in rehabilitation science, biomechanics, and human performance.

Residents who can volunteer consistent hours each week will have the chance to take part in meaningful research and potentially achieve authorship on publications. This collaboration reflects our commitment to advancing physiatric science while fostering resident involvement in high-impact projects.

Education & Outreach

Ringside Physicians - MMA
Dr. Romeo, Dr. Buchalter, Dr. Slobodian, Dr. Meagher

Sideline Physicians - Hockey



Physiatrist's Voice
NEWSLETTER December 2025

UCF/HCA/West FL Hospital PM&R Residency Program
Roberto Cordero, DO
Susan Belcher MD, Program Director
APD: Christopher Burton, MD

-continued -

This season, our residents have also teamed up with the local Pensacola Ice Flyers hockey team, serving as sideline sports physicians. This partnership allows our trainees to gain hands-on experience in acute sports medicine while supporting one of Pensacola's most exciting teams. It's another example of how our program stays engaged with the community while expanding clinical skills in real-time, fast-paced environments.

In collaboration with Island Fights 91 MMA, our residents provided ringside physician coverage, ensuring the safety and medical readiness of all athletes throughout the event. This unique opportunity allowed residents to apply their training in acute injury assessment, trauma management, and rapid clinical decision-making in a high-intensity environment, while also strengthening community engagement and visibility of the PM&R program.

Resident Wellness

Resident wellness remains a core value of our program, and this year our team has continued to strengthen connection, community, and balance both inside and outside the hospital. Recently, attendings and residents enjoyed a team-building event that featured a *"Framing the Case"* workshop to help residents refine their presentation skills on rounds, followed by the beloved annual **Dr. Cahill Movie Premiere**: a tradition led by our very own Dr. Cahill, who is not only an exceptional physician but also a film writer and actor when he's not caring for patients.

In addition to in-house wellness activities, our residents regularly participate in outings that celebrate life beyond medicine. This includes attending cultural festivals, music festivals, winery trips, celebrating holidays, birthdays, group exercise classes, and exploring the vibrant food scene across Pensacola. These shared experiences continue to foster camaraderie, recharge our team, and strengthen the supportive culture that defines our residency.

Movie Night featuring Dr. Cahill + Attendings + Residents

Pensacola Beach

UCF College of Medicine | HCA Florida Healthcare®

Physiatrist's Voice
NEWSLETTER December 2025

UCF/HCA/West FL Hospital PM&R Residency Program
Roberto Cordero, DO
Susan Belcher MD, Program Director
APD: Christopher Burton, MD

-continued -

Spinal Cord Awareness Month - Outreach

Dr. Craig running a Half-Marathon

Faculty Spotlight

Dr. Susan Belcher, MD
Hometown: Marion, Arkansas
Medical School Completed: University of Arkansas
Residency Completed: Mayo Clinic
Fellowship Completed: LSU

What has been your favorite part about UCF/HCA PM&R so far?
"I love watching our residents graduate. It is an awesome feeling to see each one succeed (matching into a great fellowship or having great job offers)."

What area of PM&R are you most excited about?
Pain Medicine

Fun Fact About You:
"I am in the movie *Glory Road*. I make the winning shot for the girls' basketball team."

Hobbies/Interests:
Triathlon, running, and boating

-continued -

Social Media

Follow us on Instagram: ucfhca_pmr for more updates and content!

Sincerely,
Roberto Cordero, DO
PGY-3 Resident Liaison

Physiatrist's Voice

NEWSLETTER December 2025

University of Florida PM&R Residency Program
Eleazar Fariscal DO Resident Liaison
Irene Estores MD, Program Director, and
Jason Zaremski MD, Assistant Program Director

Hello FSPMR Family!

Greetings from warm, hot, and sunny Gainesville, FL, (AKA The Swamp)! As we head toward the holidays and end of the calendar year, we would love to share our recent accomplishments and fun we have had during this first academic half!

Eleazar Fariscal DO

Huge congratulations to our Academic Chief Resident, Dr. Joseph Rinaldi, for recently matching into Pain Medicine Fellowship. We are tremendously proud of his successes!

Eleazar Fariscal DO Resident Liaison
Irene Estores MD, Program Director, and
Jason Zaremski MD, Assistant Program Director
- continued -

UFHealth REHAB HOSPITAL
IN AFFILIATION WITH SELECT MEDICAL

The Inpatient Rehab team got into the Halloween spirit this year.

Our PGY-2s worked on their turtle power ninja moves led by their Sensei.

UF College of Medicine
Department of Physical Medicine and Rehabilitation
UNIVERSITY of FLORIDA

Physiatrist's Voice

NEWSLETTER December 2025

Eleazar Fariscal DO Resident Liaison
Irene Estores MD, Program Director, and
Jason Zaremski MD, Assistant Program Director

- continued -

We had an amazing time at the AAPM&R Annual Assembly in Salt Lake City, Utah.

This year, we were represented by a number of residents, faculty, and alumni who served as presenters and moderator at multiple events.

UF Department of Physical Medicine & Rehabilitation
COLLEGE of MEDICINE

#aapmr25

Eleazar Fariscal DO Resident Liaison
Irene Estores MD, Program Director, and
Jason Zaremski MD, Assistant Program Director

- continued -

Dr. Abenezer Amare and Dr. Khashayar Rishsefid presented at the ASRA Annual Pain Medicine Meeting in Austin Texas

UF College of Medicine
Department of Physical Medicine and Rehabilitation
UNIVERSITY of FLORIDA

Physiatrist's Voice

NEWSLETTER December 2025

University of Florida PM&R Residency Program
Eleazar Fariscal DO Resident Liaison
Irene Estores MD, Program Director, and
Jason Zaremski MD, Assistant Program Director

- continued -



UF Department of Physical Medicine & Rehabilitation
COLLEGE of MEDICINE

Our residents learning about anatomy, spasticity management, and botulinum toxin injection sites during didactics

UFHealth REHAB HOSPITAL
IN AFFILIATION WITH SELECT MEDICAL

Dr. Ravi Ibrado and Dr. Danny Kiehl on the sidelines at one of our local football events.

Follow us on Instagram @uf_pmr for more updates and content!

https://www.instagram.com/uf_pmr/

@uf_pmr

@UF_PMR

UF College of Medicine
Department of Physical Medicine and Rehabilitation
UNIVERSITY of FLORIDA

Physiatrist's Voice
NEWSLETTER December 2025

Larkin Community South Miami PM&R Residency Program
Bhargavi Madhu DO, Resident Liaison
Jose J. Diaz, DO Program Director

Hello FSPMR Family!

Bhargavi Madhu DO

As we head into the holiday season, the Larkin South Miami PM&R residency has been busy closing out the year with momentum, new initiatives, and strong representation on the national stage.

In November, our residents and faculty were actively involved at the ASRA Pain Medicine conference. Our resident physician Bhargavi Madhu helped launch and lead "Pain Illuminated," an art-based initiative highlighting the lived experience of pain through visual media. Nearly 30 pieces were submitted, with 15 displayed in person, and the event drew enthusiastic engagement from attendees across disciplines. The project was extremely well-received, with ASRA leadership expressing interest in making it a recurring feature, and it was a proud moment of visibility for our program. Several of our residents were also recognized for their academic and society involvement, including conference awards that reflected the strength and growth of our pain-focused education. Congratulations to our Resident physicians Aagna Patel, Maria Guerrero and Roshan Santosh who received the President's Choice Award for their Retrospective Analysis: "Suzetrigine Compared with NSAIDS in Chronic Hip/Knee Osteoarthritis".

Back home, our residents continue to stay active in research, quality improvement, and community outreach while balancing inpatient and outpatient responsibilities. As we move towards the end of year, our program remains committed to expanding opportunities in pain medicine, interdisciplinary rehab, and resident-led innovation—keeping our culture focused on curiosity, collaboration, and patient-centered care.

Larkin Community South Miami PM&R Residency Program
Bhargavi Madhu DO, Resident Liaison
Jose J. Diaz, DO Program Director
- continued—

Resident Physician Bhargavi Madhu, PGY-3 presenting awards to winners of Pain Illuminated art contest at ASRAS Fall 2025 conference.

Physiatrist's Voice
NEWSLETTER December 2025

Larkin Community South Miami PM&R Residency Program
Bhargavi Madhu DO, Resident Liaison
Jose J. Diaz, DO Program Director
- continued—

Congrats to Aagna Patel and team for winning President's Choice Award at ASRA Fall 2025 Conference!!

Larkin residents learning ultrasound during didactics!!

Physiatrist's Voice
NEWSLETTER December 2025

PM&R Pioneers

Craig H Lichtblau MD

We help our early career physiatrists by providing mentors for them. We call our mentors PM&R Pioneers. These mentors are for both practice management and clinical issues. They are listed below and early career members can contact them.

What makes a PM&R Pioneer? They have a minimum of 20 years of experience and want to share their knowledge, training and experience with new FSPMR members.

If you wish to serve in this capacity and you are not yet on the PM&R Pioneers list, please submit your name to Tania Jones, FSPMR Executive Director, tjones@meyerresources.com . Thank you for your consideration and if you'd like to discuss it further with me before deciding, please contact me at C.Lichtblau@chlmd.com.

Craig Lichtblau MD

Past President Director, FSPMR

Craig Lichtblau MD	(561) 842-3694
Michael Creamer DO	(407) 649-8707
Anthony Dorto MD	(305) 932-4797
Mitchell Freed MD	(407) 898-2924
Matthew Imfeld MD	(407) 352-6121
Jesse Lipnick MD	(352) 224-1813
Thomas Rizzo Jr MD	(904) 953-2735
Mark Rubenstein MD	(561) 296-9991
Andrew Sherman MD	(305) 585-1332
Paulette Smart-Mackey MD	(321)-558-4996
Jonathan Tarrash MD	(561) 496-6622
Colleen Zittel MD	(407) 643-1329

Physiatrist's Voice
NEWSLETTER December 2025

Professional Opportunities

FSPMR will post your Professional Opportunities, whether you are looking to hire or looking for a new opportunity.

This service is FREE to FSPMR Members.

Or you can purchase an Advertisement.

Check out our [Advertisement rates:]

To post your Professional Oppor-

Physiatrist's Voice
NEWSLETTER December 2025

Professional Opportunities

Post YOUR Professional Opportunities here

With 3 months of newsletter advertising, your ad will also appear on FSPMR's website for that same 3-month period.

FSPMR – 2025 Advertising sizes:

Full page - $1000
(7.5"w x 10"h)

540 px x 720 px Resolution 72 px/inch
2,250 px x 300 px Resolution 300 px/inch

Half page - $750
Horizontal: 7.5"w x 4.75"h
540 px (w) x 342 px (h) Resolution 72 px/inch
2,250 px (w) x 1425 px Resolution 300 px/inch

Vertical: 4.0"w x 9"h
288 px (w) x 648 px (h) Resolution 72 px/inch
1200 px (w) x 2700 px (h) Resolution 300 px/

One third page - $500
Horizontal: 7.5"w x 3"h
540 px (w) x 216 px (h) Resolution 72 px/inch
2250 px (w) x 900 px (h) Resolution 300 px/inch

Vertical: 2.8"w x 9"h
202 px (w) x 648 px (h) Resolution 72 px/inch
840 px (w) x 2700 px (h) Resolution 300 px/inch

File Types Accepted: Adobe PDF (.pdf), or Photoshop (.psd).

ALL FILES Flattened

Also accepted, .tiff and .jpg.



Professional Opportunities are FREE and re-posted as a service to FSPM&R members

Physiatrist's Voice

NEWSLETTER December 2025

Deadline for our next issue, is February 15th 2026 for our March 2026 Newsletter

Guidelines for your articles are available on the website: FSPMR.org/newsletters Here a few for your convenience;

- **Pictures: should be in .jpg or .gif format. All files must have minimum resolution of 72 dpi. (max. 300) with a image size no larger than: 1500 px x 900 px**
- **Documents should be submitted in electronic format (.docx). FONT: Georgia pt 11.**
- **All articles will be approved by Newsletter editors.**
- **FSPMR will retain full editorial rights to any submissions.**

Newsletter Disclaimer:

Articles in this newsletter are not an endorsement of nor an acceptance by the Florida Society of Physical Medicine and Rehabilitation. They are published as a service to the author for the benefit of members. This is not a scientifically peer reviewed publication.

FSPMR Office: 407-924-6568
Executive Director: Tania M. Jones
tjones@meyerresources.com