



**Enhancing Health And Function Through  
Education And Research In The Field Of  
Physical Medicine And  
Rehabilitation**

# PHYSIATRIST'S VOICE

NEWSLETTER

DECEMBER 2018



**PRESIDENT'S MESSAGE**  
**CRAIG H. LICHTBLAU, M.D.**

At this time, the Florida Society of Physical Medicine and Rehabilitation Board of Directors has decided to make great steps and strides in helping young physiatrists to start and manage their practices. This is one example of why a physiatrist graduating from a residency training program or a new physiatrist coming to the State of Florida

should become an active member of the Florida Society of Physical Medicine and Rehabilitation (FSPMR).

I have been in practice approximately 29 years and I have seen changes in the private practice of medicine, the laws, regulations, and changes in physician monitoring. Every year it seems to be a little more difficult to practice.

## IN THIS ISSUE

PRESIDENT'S MESSAGE.....	1-2
RESIDENT'S SECTION.....	3 - 10
SPOTLIGHT.....	7
ARTICLE BY DR. LICHTBLAU: OSSTEointegratoIN.....	11 - 13
ARTICLE BY DR. LICHTBLAU: CONGENITAL FEMORAL DEFICIENCY (ARTICLE)....	14-18
(PICTURES)...	18-22
JOB OPPORTUNITIES .....	23

One of the benefits of being a member of the Florida Society of Physical Medicine and Rehabilitation is to receive the quarterly newsletter, *Physiatrist's Voice*, which is designed to keep physiatrists in the State of Florida up to date on changes in laws, rules and regulations, which in turn will help physiatrists be aware of the current pitfalls in the private practice of medicine.

One of the new vehicles contained in the newsletter will be the Florida PM&R Pioneers. In order to be a Florida PM&R Pioneer, the physician has to be a current member of FSPMR and has to have a minimum of 20 years of experience. If you have a minimum of 20 years of experience and you want to share your knowledge, training and experience with new FSPMR members, please submit your name and area of expertise to [C.Lichtblau@chimd.com](mailto:C.Lichtblau@chimd.com). A special thanks to FSPMR's Board of Directors who have volunteered to be Florida PM&R Pioneers (with the exception of a couple of our younger members who have not yet practiced 20 years!).



# PHYSIATRIST'S VOICE

NEWSLETTER

DECEMBER 2018

PRESIDENT'S MESSAGE CONTINUED  
(CONTINUED FROM PREVIOUS PAGE)

Florida PM&R Pioneers would not be expected to advise or guide specific patient care (i.e. curbside consultations on specific patients), or legal matters, but rather, to share pearls of wisdom on practice management and medically guiding the approach to patient care and physician education.

Florida PM&R Pioneers will create bridges between the newer and the more experienced generation of Florida Physiatrists. This will make a lasting impact on the State of Florida's healthcare for PM&R patients. Florida PM&R Pioneers will advance the professional growth of younger colleagues by providing guidance in a rapidly changing healthcare environment in our state. Florida PM&R Pioneers will share many years of valuable clinical knowledge to the younger generation. Once you contact me (C.Lichtblau@ch1md.com) your name will go on the list of Florida PM&R Pioneers. The list will be printed in the next quarterly newsletter and young physicians and new physicians that are starting practices will have the ability to contact you.

It is very important for members of the Florida Society of Physical Medicine and Rehabilitation to inform physiatrists who are non-members that there are great advantages of becoming a member of the FSPMR and this is just one example.

We have begun a Member Spotlight this issue.

There are plans to start an additional new section of FSPMR's newsletter which will include rehabilitation research going on in the State of Florida. And we always include updates from the three residency training programs that are in the State of Florida. We are aware there is a fourth PM&R residency training program which has begun their first year at Memorial Healthcare in Hollywood. By this time next year, we plan to include updates from their program as well.

Please be advised that the invoices for 2019 dues will have gone out by the time this newsletter issue is published. You can go to the Florida Society of Physical Medicine and Rehabilitation website and you may pay your dues online here: <http://www.fspmr.org/join-renew-payment.html>.

Please, everybody pay your dues as soon as possible so our transition into 2019 will be seamless.

*The Happiest of Holidays to Everyone!*



# PHYSIATRIST'S VOICE

NEWSLETTER

DECEMBER 2018

RESIDENTS' SECTION

Greetings from the University of Miami Miller School of Medicine / Jackson Memorial Hospital PM&R Residency Program!

We were happy to connect with new and old friends at the recent American Academy of Physical Medicine & Rehabilitation Annual Assembly in Orlando last month.






# PHYSIATRIST'S VOICE

NEWSLETTER

DECEMBER 2018

RESIDENTS' SECTION CONTINUED  
(CONTINUED FROM PREVIOUS PAGE)



It was an honor to have so many of our residents presenting posters:

- The Effect of Amniotic Fluid Allograft Injection in Knee Osteoarthritis: A Case Series. Tokarz, T; Charnoff J; Aviles X.
- Outcome of Sciatic Nerve Repair with Human Schwann Cells: First Experience with Two Human Cases. Dididze, M; Levi, A; Anderson, K.
- Spinal Accessory and Suprascapular Nerve Injury Following Human Bite: A Case Report. Dididze, M, Ward, B, Ramos-Vargas, K.
- Severe Ataxia Secondary to Bariatric Beriberi: A Case Report. Weaver, M; Shapiro, L.
- Alien Hand Syndrome Complicated by Contralateral Limb Apraxia: A Case Report. Weaver, M; Alvarez, G.
- Resident Education of Ultrasound Guided Procedures: A Homemade Practice Model. Charnoff, J; Naqvi U; Weaver, M; Price, C.
- A Novel Approach for Fluoroscopic Guided Intra-articular Hip Injection: A Technique Description and Case Series. Cross, A; Castaneda, P; Sherman, A.

We were also excited to have our faculty member, Dr. Lauren Shapiro, lead an interesting Practice Symposium on "Emergency Preparedness for People with Disabilities."

With fellowship interview season still progressing, we are proud to announce that many of our gradu-



# PHYSIATRIST'S VOICE

NEWSLETTER

DECEMBER 2018

RESIDENTS' SECTION CONTINUED  
(CONTINUED FROM PREVIOUS PAGE)

ating residents have already matched into prestigious fellowships:

Christopher Alexander, MD PGY4 Chief Resident – Dartmouth-Hitchcock; Pain Medicine  
Jesse Charnoff, MD PGY4 Chief Resident – Hospital for Special Surgery; Sports and Spine  
Andrew Chang, MD PGY4 – Thomas Jefferson University (Sidney Kimmel); Pain Medicine  
Aaron Cross, MD PGY4 – University of Miami / Jackson Memorial Hospital; Pain Medicine

Finally, our resident of the quarter award was presented to Martin Weaver, MD PGY3.

**Martin Weaver, MD**  
**PGY-3 Resident**  
**FSPMR Liaison**

Andrew Sherman, MD, MS  
FSPMR Treasurer

The national American Academy of Physical Medicine and Rehabilitation 2018 conference was held in Orlando, Florida over the week of October 25-28. Our second, third and fourth year residents were all in attendance. They had a great time exploring all the learning opportunities that were available. The residents also setup a table at the residency fair and met medical students from across the country who are interested in the PM&R field.






# PHYSIATRIST'S VOICE

NEWSLETTER

DECEMBER 2018

RESIDENTS' SECTION CONTINUED  
(CONTINUED FROM PREVIOUS PAGE)

There is a lot of research happening at The University of South Florida. Second year residents Krystal Yankowski and Elizabeth Mortazavi as well as Program Director Marissa McCarthy are currently involved in a research project entitled "Chemodeneration of eccrine glands for the treatment of hyperhidrosis of residual limbs of amputees." They submitted an abstract on their research to the Association of Academic Physiatrists and it was accepted for poster presentation at the AAP annual meeting in Puerto Rico in February 2019. Several other residents also had abstracts accepted for the annual AAP conference. Fourth year Morgan Pyne had a poster accepted that is titled "Interest in rehabilitation services over telemedicine." Third year resident Amanda Hanekom had a poster accepted that is titled "A case of intractable restless leg syndrome following unilateral caudate injury." And third year resident Anabel Anon-Vila had a poster accepted that is titled "Capsulorrhaphy for treatment of ganglion cyst of the wrist: a case series."



Fourth year resident Morgan Pyne has taken the initiative to start the first outpatient Telemedicine clinic at the James A Hayley VA. Now veterans who cannot easily make appointments at the VA have access to telemedicine and can follow up easily with physicians from their home. Fourth year resident Eric Catlin was recently accepted into the USF Pain Fellowship program and will be starting in 2019.

Interview season for the next class of residents is officially under way and we look forward to the new year ahead!



# PHYSIATRIST'S VOICE

NEWSLETTER

DECEMBER 2018

MEMBER SPOTLIGHT

## FSPMR Spotlight:



Morgan Pyne DO - PGY4 University of South Florida PM&R Residency

Morgan is a Florida native that has kept her roots. She attended the University of South Florida where she majored in biomedical sciences and was a student athlete on the Bulls tennis team. She went on to Lake Erie College of Osteopathic Medicine in Bradenton and then to the University of South Florida for their PM&R Residency. Morgan served as FSPMR's first Resident Liaison from USF, helping connect new physiatrists to FSPMR and offering insights and resources for residents. She has kept FSPMR up to date on changes and advancements at the USF PM&R Residency program and had the opportunity to speak at the annual conference last year. She has physiatric interests in spinal cord injury and adaptive sports and has been accepted in the spinal cord fellowship at the U.S.F./Haley VA which she plans to attend next year.

SAVE THE DATE

JULY 18 - 21 2019

THE DIPLOMAT BEACH RESORT HOTEL, HOLLYWOOD, FL

FLORIDA SOCIETY OF PHYSICAL MEDICINE AND  
REHABILITATION  
2019 ANNUAL MEETING AND CONFERENCE

IN CONJUNCTION WITH THE

FLORIDA SOCIETY OF INTERVENTIONAL  
PAIN PHYSICIANS ANNUAL MEETING,  
CONFERENCE & TRADESHOW



&





# PHYSIATRIST'S VOICE

NEWSLETTER

DECEMBER 2018

RESIDENTS' SECTION CONTINUED  
(CONTINUED FROM PREVIOUS PAGE)


Larkin PM&R residents attended the AAPM&R Annual Assembly, held in Orlando, Florida. Residents were able to experience the job fair, learn new interview techniques, as well as sit in on some interactive lectures, including one on Kinesio taping. Wesam Mohamed, PGY4 presented a poster entitled "Complex Regional Pain Syndrome Developing After Anterior Spinal Artery Syndrome: A Case Report" as well.

We had an OMT workshop earlier in the year and were able to hone our osteopathic skills for our future practice with the assistance of the NMM residents.



Residents during our OMT workshop

Additionally, we were able to participate in an educational dinner with Encompass Health to discuss available practice opportunities and different business models in physiatry.



Residents and guests at Encompass Health dinner.





# PHYSIATRIST'S VOICE

NEWSLETTER

DECEMBER 2018

RESIDENTS' SECTION CONTINUED  
(CONTINUED FROM PREVIOUS PAGE)

LECOM/Larkin PM&R is seeking Florida physiatrists interested in clinical and didactic exposure. If you would like to learn more about opportunities to become an Assistant Clinical Faculty, Associate Professor, or present a lecture in your field of expertise, please contact the PM&R Program Director, Jose Diaz, DO ([josediaz@larkinhospital.com](mailto:josediaz@larkinhospital.com)) and Ernesto Alfonso ([ealfonso@larkinhospital.com](mailto:ealfonso@larkinhospital.com)) the GME Program Coordinator.



Celebrating Physiatry Day 2018 at the AAPMR Annual Assembly. (Left to right: Marjorie Mamsaang, PGY4, Shiel Jhaveri, PGY4, Karen Rosen, PGY3)

Residents attending Neurotoxin Conference at Cleveland Clinic (Left to right: Trevor Persaud, PGY1, Alek Pecher-ek, PGY1, Colleen Neubert, PGY1)






# PHYSIATRIST'S VOICE

NEWSLETTER

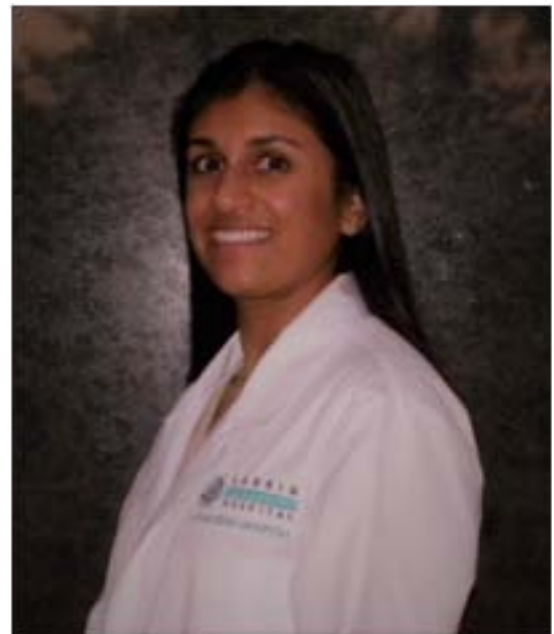DECEMBER 2018

RESIDENTS' SECTION CONTINUED  
(CONTINUED FROM PREVIOUS PAGE)



Wesam Mohamed, PGY4 presenting at AAPMR Annual Assembly with his poster entitled "Complex Regional Pain Syndrome Developing After Anterior Spinal Artery Syndrome: A Case Report"

Shiel Jhaveri, DO PGY-4  
Larkin Community Hospital  
Department of PM&R  
AOCPMR Resident Council  
Social Media Chair





ARTICLE BY DR LICHTBLAU  
OSSEOINTEGRATION

### Osseointegration: A Novel Technology for Amputees

*Editor's Note: What follows is the final draft before it was published earlier this year in the International Journal of Physical Medicine and Rehabilitation: Lichtblau and Hennekens, Int J Phys Med Rehabil, 6:5, DOI: 10.4172/2329-9096, 1000490.*

#### **Craig Lichtblau MD**

President, Florida Society of Physical Medicine and Rehabilitation

Medical Director, Osseointegration Program at Paley Orthopedic and Spine Institute, West Palm Beach, Florida

#### **Charles H Hennekens, MD, DrPH**

First Sir Richard Doll Professor & Senior Academic Advisor to the Dean

Charles E. Schmidt College of Medicine, Florida Atlantic University

#### **Funding:** None      **Disclosures:**

Dr. Lichtblau reported that he is funded by his private practice of physical medicine and rehabilitation.

Professor Hennekens reported that he is funded by the Charles E. Schmidt College of Medicine of Florida Atlantic University; serves as an independent scientist in an advisory role to investigators and sponsors as Chair or Member of Data and Safety Monitoring Boards for Amgen, British Heart Foundation, Cadila, Canadian Institutes of Health Research, DalCor, Regeneron, and the Wellcome Foundation, as well as to the United States (U.S.) Food and Drug Administration, and UpToDate; and receives royalties for authorship or editorship of 3 textbooks and as co-inventor on patents for inflammatory markers and cardiovascular disease that are held by Brigham and Women's Hospital; and has an investment management relationship with the West-Bacon Group within SunTrust Investment Services, which has discretionary investment authority and does not own any common or preferred stock in any pharmaceutical or medical device company.

\*\*\*\*\*

When the totality of evidence is complete, clinicians can make the most rational decisions for their individual patients and policy makers can do so for the health of the general public. (1) Further, for the reliable detection of small to moderate effects, which are clinically worthwhile and can have a major public health impact, large scale randomized evidence is crucial.(2) When the totality of evidence is incomplete it is appropriate to remain uncertain but, nonetheless, clinicians and policy makers are often faced with decision making.

Osseointegration is derived from the Greek "osteon" meaning bone and the Latin "integrare" which means to make whole. The term is defined as a direct contact between living bone and the surface of the load-bearing titanium implant. Since 1995, osseointegration for amputees has been in clinical use. Osseointegration can be performed on any extremity amputation, including femur, tibia, humerus and radius/ulna. This novel technique utilizes a skeletal integrated titanium implant which is connected through an opening in the stump to an external prosthetic limb. This allows direct contact to the ground, which provides greater stability, more control, and minimizes energy consumption. (3)

Today, when a patient undergoes an amputation, the component parts (socket, knees, feet, hands) are much



# PHYSIATRIST'S VOICE

NEWSLETTER

DECEMBER 2018

ARTICLE BY DR LICHTBLAU  
OSSTEINTEGRATION  
(CONTINUED FROM PREVIOUS PAGE)

more sophisticated than they were years ago. The distal stump shrinks and expands, and the socket becomes too tight or becomes too loose and in many instances is the source and the cause for skin breakdown and infection. Prosthetic devices are heavy because the device requires a socket for attachment. Because the artificial limb is attached with a socket, proprioception for the extremity is completely lost.

This titanium implant is modeled on the anatomy of the human body and takes the load back directly to the bone, the joint above, and associated muscles. This titanium implant allows the prosthetic device to be taken on and off with a simple quick and safe connection between the stump and the lower prosthesis. No longer is the prosthetic device attached to you, but it becomes a part of you, resulting in much greater comfort and walking control as proprioception is gained in the extremity.

Taking on and off the prosthesis is very easy and takes less than ten seconds. Due to the solid fixture to the bone it accurately connects in the exact spot each and every time you attach the prosthesis. This device can be used with all types of prosthetic componentry. With this new technology the days of fiddling around with time consuming and cumbersome suction, socks and liners is over. Using this titanium bone implant allows for natural loading of the hip joint and the femur, which encourages bone growth and creates a more natural gait and requires less physical exertion. Any weight gain or fluid variations of the distal stump have no effect on the use of the prosthetic limb. It eliminates the bulky socket providing a much more natural streamlined look in clothes. This device allows for full freedom of movement from walking to cycling and recreational activities. Muscular strength is developed freely, which minimizes muscle wasting of the distal stump. Movement of the affected extremity is not restricted by the protruding edges of a socket, allowing for greater ease and comfort sitting, standing and walking. The direct connection between the femoral bone implant and knee enables free natural pivoting movements. The knee prosthesis can be easily attached and removed within just a few seconds. Because the titanium implant goes directly into the bone, the patient regains the ability to feel the ground and can differentiate between different surfaces such as carpet, grass, tile and uneven ground, which also allows for movement in unfamiliar areas in dim light.

A poorly fitting socket can increase an amputee's energy consumption by 100%. Surgery is usually a single procedure followed by early mobilization a few days after the surgery, allowing rapid recovery and minimizing the time spent away from normal day to day activities. In some cases, a two-stage procedure is required with a short interval of six to eight weeks between the first and second stage surgeries followed by an early mobilization rehabilitation program. This type of implant for amputees makes a conventional socket in a prosthetic device unnecessary.

As there are no large scale randomized trials directly testing the efficacy of this promising, but unproven technology has not yet been approved by the United States (US) Food and Drug Administration. The necessary evidence should accumulate from three centers of excellence in the US which will conduct the necessary research to complete the totality of evidence. These include the Paley Institute in West Palm Beach, Florida, the University of California San Francisco, and the Uniformed Services University.

The Paley Institute is the number one extremity reconstruction clinic in the world and receives referrals from all 50 US states and over 90 countries from around the world. The University of California San Francisco is the first US center to have begun Osseoanchored Prosthesis for the Rehabilitation of Amputees (OPRA) program.



# PHYSIATRIST'S VOICE

NEWSLETTER

DECEMBER 2018

ARTICLE BY DR LICHTBLAU  
OSSTEINTEGRATION  
(CONTINUED FROM PREVIOUS PAGE)

The Department of Defense Osseointegration Program transitioned from translational research into the clinic in 2016 with Uniformed Services University serving as the coordinating center for the clinical program. Thus, a sufficient totality of evidence that includes large scale randomized trials should emerge after the next few years. The clinical and policy implications of gathering a sufficient totality of evidence are large. Specifically, 2.1 million Americans have experienced limb loss and it is estimated that the prevalence will double in the next several decades. (4,5) Each year, in the US alone, 185,000 amputations are performed. Further, 1558 military personnel have lost limbs during the wars in Afghanistan and Iraq (5). In addition, however, the epidemic of type 2 diabetes (6) which is due primarily to the increasing prevalence of obesity (7), continues to increase at alarming rates in the US and worldwide. Over 50% of patients with diabetes who undergo limb amputation will require an amputation of the other leg within the next few years (5). Of persons with diabetes who have a lower extremity amputation, over 50% will require amputation of the second leg within 2-3 years. With respect to costs, hospital charges alone totaled over \$8 billion and the lifetime health costs of amputees is over \$500,000 or 2/3 higher than those without limb loss. Finally, insurance costs in the US alone are \$12 billion annually. (5,8)

It is plausible that osseointegration turns out to be a “beautiful hypothesis slain by ugly facts” (7), but it is equally plausible that this novel technology will provide enormous benefit to the amputees who pose enormous as well as increasing clinical and policy challenges in the US and worldwide.

## REFERENCES

1. Hennekens CH, DeMets D: Statistical association and causation: Contributions of different types of evidence JAMA, 2011, 306:1134-1136.
2. Hennekens CH, DeMets D: The need for large scale randomized evidence without undue emphasis on small trials, meta-analyses or subgroup analyses. JAMA, 2009, 302:2361-2362.
3. Thesleff A, Branemark R, Hakansson B, Ortiz-Catalan M. Biomechanical characterization of bone-anchored implant systems for amputation limb prostheses: A systematic Review Ann Biomed Eng, 2018, 46:377-391.
4. Ziegler-Graham K, MacKenzie EJ, Ephraim PL, Travison TG, Brookmeyer R. Estimating the Prevalence of Limb Loss in the United States: 2005 to 2050. Archives of Physical Medicine and Rehabilitation 2008;89(3):422-9.
5. Amputee-Coalition. "Limb Loss in the USA." Inside Track, 01/04/2016, 3.
6. Hennekens CH, Pfeffer M, Newcomer J, Jellinger P, Garber A: Treatment of Diabetes Mellitus: The urgent need for multifactorial Interventions. Am J Manag Care. 2014 May;20(5):357-9. PMID: 25181565.
7. Hennekens CH, Andreotti F: The leading avoidable cause of premature mortality in the world: the case for obesity. Am J Med. 2013 Feb 126(2):97-8. PMID: 23331433
8. HCUP Nationwide Inpatient Sample (NIS). Healthcare Cost and Utilization Project (HCUP). Rockville, MD: Agency for Healthcare Research and Quality; 2009
9. Huxley TH (1894) Collected Essays of Thomas Huxley: Discourses Biological and Geological Part Eight New York: Kessinger Publishing



ARTICLE BY DR LICHTBLAU  
CONGENITAL FEMORAL DEFICIENCY

### CONGENITAL FEMORAL DEFICIENCY (PROXIMAL FEMORAL FOCAL DEFICIENCY)

Proximal Focal Femoral Deficiency (PFFD) is part of a spectrum of congenital deformities affecting the femur more comprehensively named congenital femoral deficiency (CFD).

CFD may range from simple shortening of the normal-appearing femur to the complete absence of the proximal two-thirds of the bone. Deficiencies of the hip and knee joint often coexist and are determinates for appropriate treatment. Treatment of this condition is complex and should be undertaken in a specialized center with experience in congenital deformities. Most all patients with CFD will require a combination of surgical and/or orthotic treatment. Complex reconstructions and limb lengthening up to 25 to 30 cm is possible for patients with reconstructible hip and knee joints.

In patients with severe deformity, limb modification may be an option. This seems to level the ankle on the involved side with the knee of the uninvolved side at maturity and may include different techniques including and not limited to: foot ablation, knee and/or hip arthrodesis or rotationplasty.

Congenital deficiency of the femur (CFD) is a spectrum of disorders which includes proximal focal femoral deficiency (PFFD), Coxa vara, hypoplastic and congenital short femur. CFD is considered to be a failure of formation and is grouped with transverse limb deficiencies. The exact etiology of congenital femoral deficiency is unknown.

PFFD is a distinct subset of CFD where the deficiency is mainly proximal. The bone is globally shortened and often smaller than the opposite side. The femoral head may or may not be present. There may or may not be continuity in the femoral neck. Contractures of the hip and knee exist often in are variable in severity. PFFD may coexist with congenital knee instability, fibular hemimelia and foot deformities.

#### CLINICAL FINDINGS:

The degree of shortening of the femur is variable, but generally gives rise to a thick bulky thigh. Classic deformity in patients with moderate to severe PFFD is a contracture of the hip joint in flexion, external rotation and abduction. This brings the lower limb anterior to the weightbearing axis of the body and causes a decrease in the efficiency of the lower extremity lever arm.



ARTICLE BY DR LICHTBLAU  
CONGENITAL FEMORAL DEFICIENCY

(CONTINUED FROM PREVIOUS PAGE)

PFFD/CFD

Page 2

### **RADIOGRAPHIC EXAMINATION:**

Femur is shortened and the femoral head may or may not be present depending on the degree of deficiency. There may be a radiolucency in the proximal femur usually in subtrochanteric region. This generally represents delayed ossification, Coxa vara may be present and the distal femoral condyles may be hypoplastic as well.

### **CLASSIFICATION:**

Dr. Dror Paley does not consider PFFD as a separate entity, but classifies CFD according to factors that affect choices for complex reconstruction. Dr. Paley feels that knee joint mobility and deficiency also substantially impact treatment.

In Type I there is an intact femur with mobile hip and knee, ossification of the proximal segment and Type 1-A femurs is normal and that in Type 1-B femurs is delayed.

In Type 2 there is a proximal mobile pseudoarthrosis accompanied by a mobile knee. In Type 2-A there is a femoral head and acetabulum which is mobile. In Type 2-B it is either absent or stiff.

Type 3 is a deficiency of the shaft of the femur and its two subtypes 3-A and 3-B are determined by the extent of knee mobilization (greater than 45° in 3-A and less than 45° in 3-B).

Dr. Paley feels that Type 1 femurs are most amenable to lengthening and reconstruction. It should have all hip and knee deformities addressed before treatment is undertaken.

CFD is a complex problem where treatment options will vary from case to case. Each of these children is unique and will benefit from a tailored multidisciplinary approach that combines nonoperative orthotic and surgical treatment to maximize function.

The first step in establishing a treatment plan should be to determine whether the patient is a candidate for limb lengthening or limb modification. In order to be suitable for limb lengthening, the expected limb length discrepancy at maturity should be acceptable and the hip and knee joint should be either stable or reconstructible. Limb modification includes partial amputations, arthrodesis and rotationplasty. Almost all children with PFFD will utilize some form of orthotic at some point in their lives.



ARTICLE BY DR LICHTBLAU  
CONGENITAL FEMORAL DEFICIENCY

(CONTINUED FROM PREVIOUS PAGE)

PFFD/CFD

Page 3

Nonoperative observation bracing and prosthetic fitting should be employed while waiting for the child to reach appropriate age for surgery or between episodes of surgical treatment. The principle goal of bracing is to establish stable weightbearing extremity and may require nonstandard or unconventional braces produced to accommodate the shortened and deformed high compensate for hip and knee instability and provide a stable base for weightbearing.

### **OPERATIVE TREATMENT:**

The Paley classification broadly addresses treatment and suggests that Type 1 and 2-A femurs can be successfully treated with complex reconstruction. Type 2-B femurs can be treated with lengthening and pelvic support osteotomy or at times amputation or rotationplasty can be considered for the extensively shortened Type 3 femurs with incompetent knee and hip joints.

Anticipated growth of both extremities should be calculated and a clear idea of the final limb length discrepancy be established before either treatment is selected. By utilizing modern limb lengthening techniques, successful total lengthening of up to 20-30 cm has been previously reported in these children. These require multiple episodes of lengthening and is often accompanied by contralateral epiphyseodesis limb lengthening. Limb salvage in these children include correction of the limb length discrepancy which can be significant.

Hip and knee stability must be properly addressed to avoid devastating complications during lengthening. Under-coverage of the acetabulum can be treated with acetabuloplasty prior to lengthening. Knee instability can be treated with soft tissue reconstruction or bridging the fixator across the knee during lengthening. Coxa vara can be treated with valgus osteotomy. If pseudoarthrosis of the proximal tibia exists, it must be treated and stable union achieved. Once these prerequisites have been met, limb lengthening procedures may be scheduled.

The profound shortness of the femur may dictate that multiple sessions of limb lengthening be performed throughout childhood to achieve similar length of both limbs.

### **LIMB MODIFICATION:**

If the deficiencies of the femur and adjacent joints are too severe to allow successful lengthening or if the family does not want to pursue a complex reconstructive process, surgical treatment should focus on achieving stable lever arm with the bearing of weight. This may require arthrodesis of the hip and/or knee or pelvic support osteotomy. The main goal for limb modification is to insure that the ankle is at the level of the normal knee at maturity to allow for more advantageous prosthetic fitting and lesser energy expenditure with ambulation.





ARTICLE BY DR LICHTBLAU  
CONGENITAL FEMORAL DEFICIENCY

(CONTINUED FROM PREVIOUS PAGE)

PFFD/CFD

Page 4

Amputation in children with PFFD usually consists of ablation of the foot in a Boyd and Syme amputation. As growth occurs growth in the foot adds length that is not advantageous to weightbearing and which interferes with prosthetic fitting.

In rotationplasty the lower extremity is rotated 180° through the remaining femur and/or an arthrodesed tibia in order to allow the ankle joint to function like the knee. The foot after rotationplasty functions as would the residual tibia in a below knee amputation; therefore, providing the patient with more advantageous mobility. While it can be considered an unconventional approach, rotationplasty has held its place as a viable alternative in PFFD as well as for children with tumors of the proximal lower extremity requiring wide resections.

Several reports have underlined the fact that children who underwent rotationplasty have favorable functional and quality of life outcomes and are usually accepting of the cosmetic result. Studies have found that rotationplasty patients measure more favorably than above the knee amputees functionally both regard to oxygen consumption and that their gait is faster and more symmetric.

The prerequisites of a successful rotationplasty include a mobile and sensate foot, ankle mobility within the functional range and adequate plantar flexion strength. If there is inadequate pelvic stability, the femur can be fused proximally.

Children with bilateral PFFD make up a unique subset for this deformity and require a different approach to treatment as they will most likely choose not to make use of a prosthesis during their lives.

Limb length inequality and foot problems make up the bulk of their problems and should be addressed with proper surgical treatment according to the patient's needs and wishes.

PFFD and CFD are members of the family of complex deformities and should be considered to involve not just the femur, but the entire lower extremity. Today's treatment options may allow these children to achieve a level of function that was unimaginable in the past decades. However, treatment remains lengthy and complex and requires full participation from the patient and family along with an experienced and competent multidisciplinary team to address all aspects of this complex deformity.



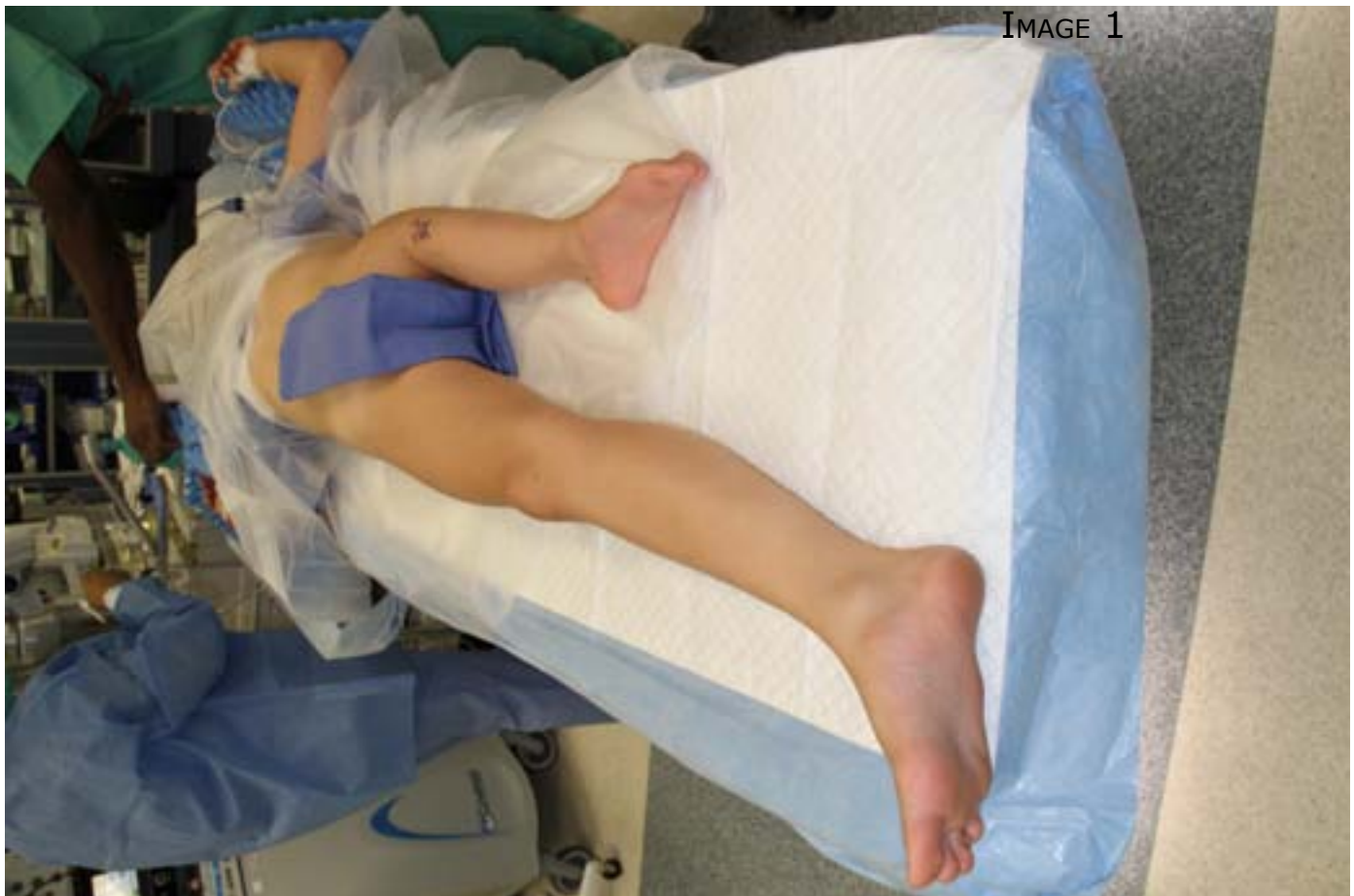ARTICLE BY DR LICHTBLAU  
CONGENITAL FEMORAL DEFICIENCY  
(CONTINUED FROM PREVIOUS PAGE)

PFFD/CFD  
Page 5

Treatment for congenital femoral deficiency (Proximal femoral focal deficiency) should be undertaken in a specialized center with experience in congenital deformities.

The Paley Orthopaedic and Spine Institute at St. Mary's Medical Center in West Palm Beach, Florida is a world renowned medical center that receives referrals from 50 states and over 90 countries from around the world.

The mission of the Paley Institute is to provide the most technologically advanced treatments to improve the lives of those who suffer from congenital developmental and posttraumatic orthopedic conditions. The treatment philosophy focuses on reconstruction over amputation and a commitment to preserving limbs and joints and restoring function.





# PHYSIATRIST'S VOICE

NEWSLETTER

DECEMBER 2018

ARTICLE BY DR LICHTBLAU  
CONGENITAL FEMORAL DEFICIENCY  
(CONTINUED FROM PREVIOUS PAGE)

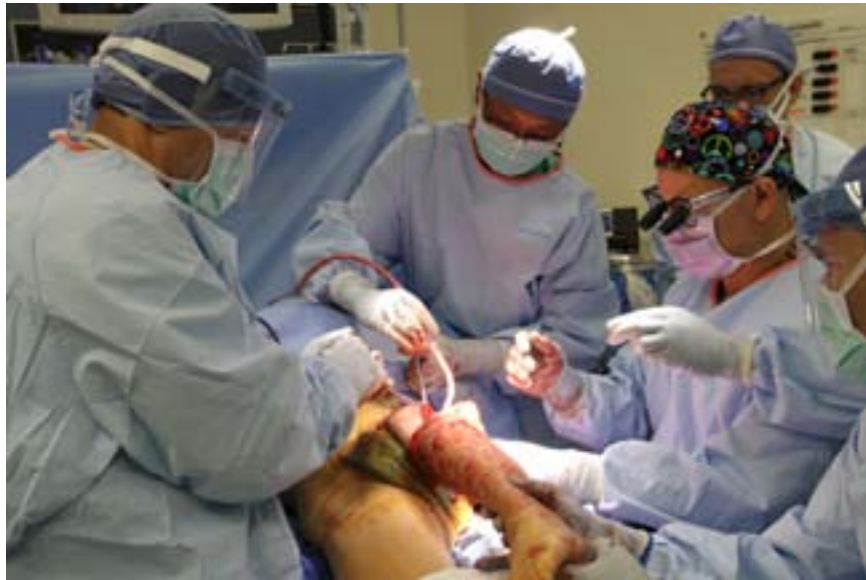

IMAGE 2

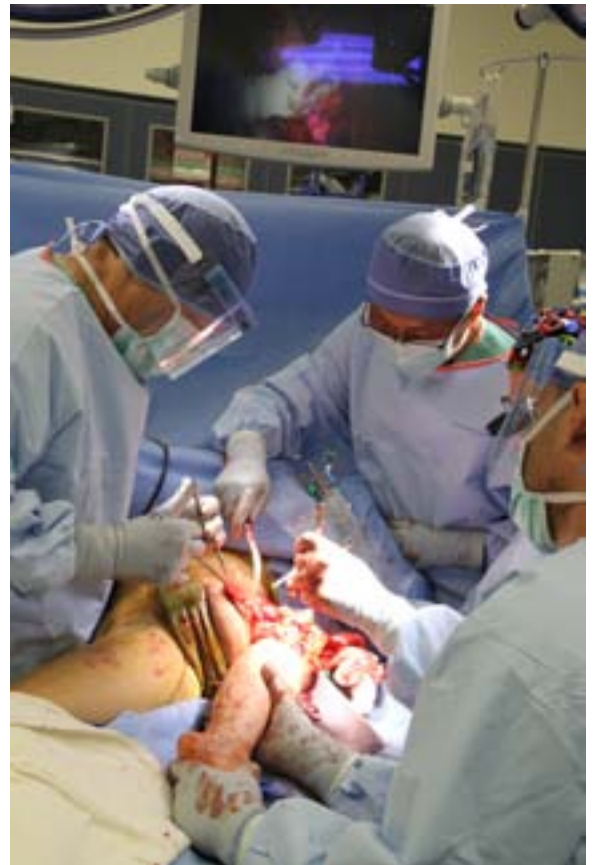

IMAGE 4

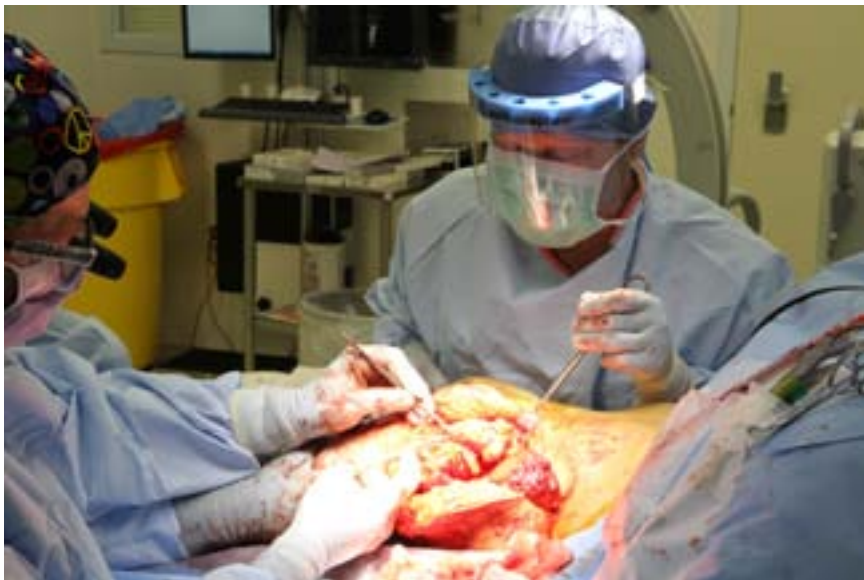

IMAGE 3



# PHYSIATRIST'S VOICE

NEWSLETTER

DECEMBER 2018

ARTICLE BY DR LICHTBLAU  
CONGENITAL FEMORAL DEFICIENCY

(CONTINUED FROM PREVIOUS PAGE)

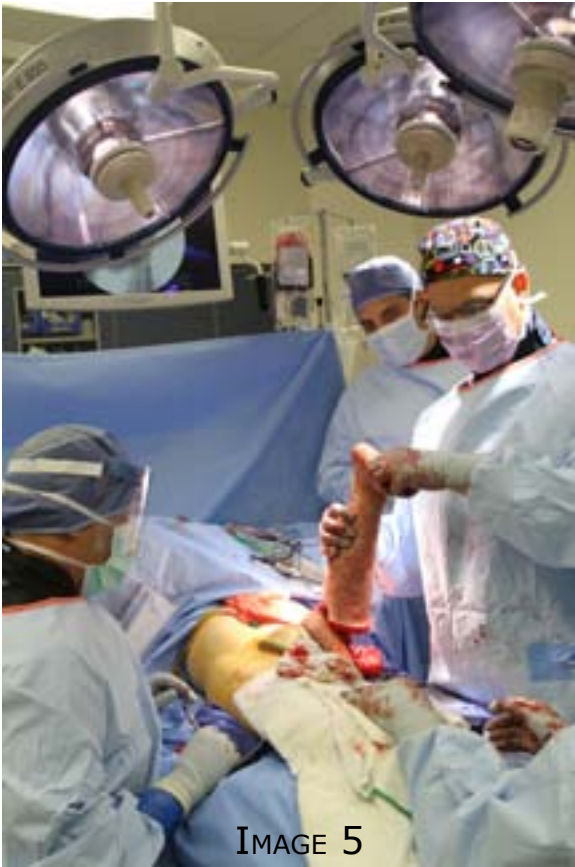

IMAGE 5

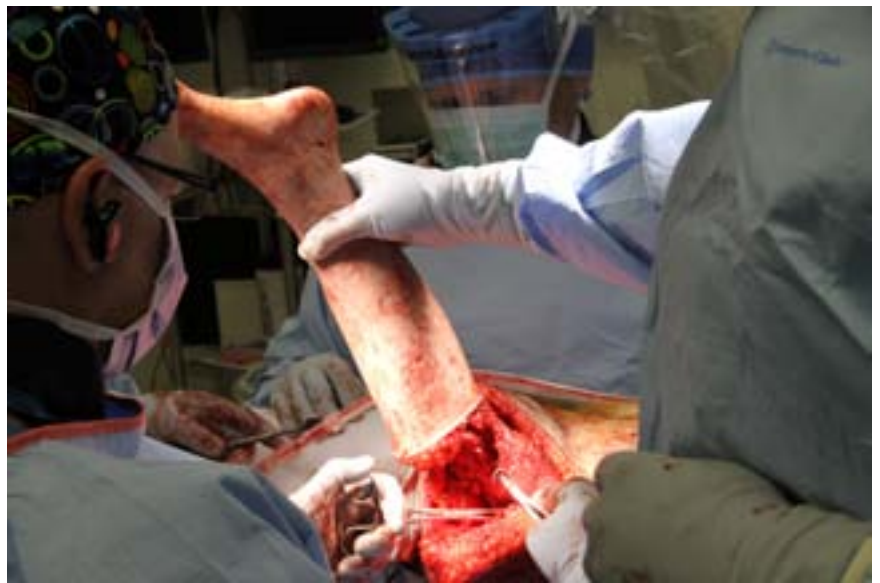

IMAGE 6

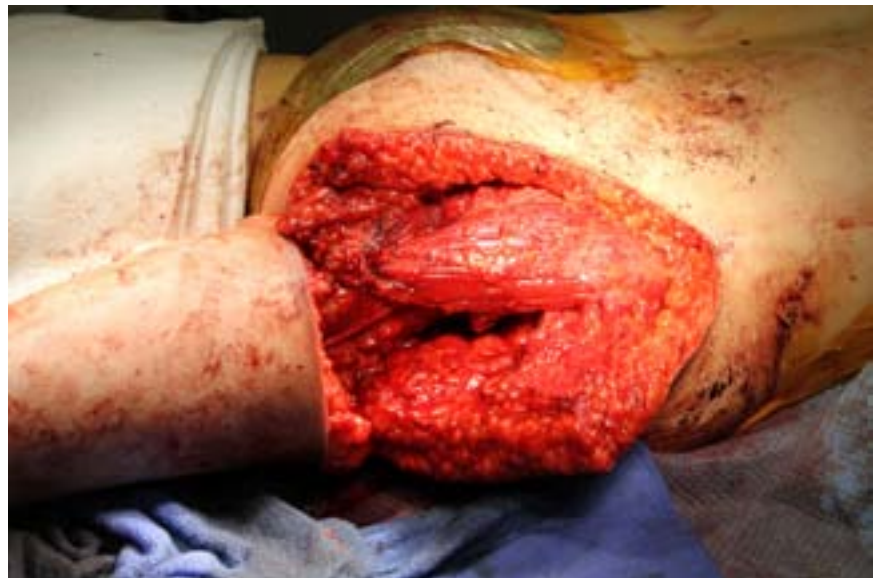

IMAGE 7



# PHYSIATRIST'S VOICE

NEWSLETTER

DECEMBER 2018

ARTICLE BY DR LICHTBLAU  
CONGENITAL FEMORAL DEFICIENCY

(CONTINUED FROM PREVIOUS PAGE)

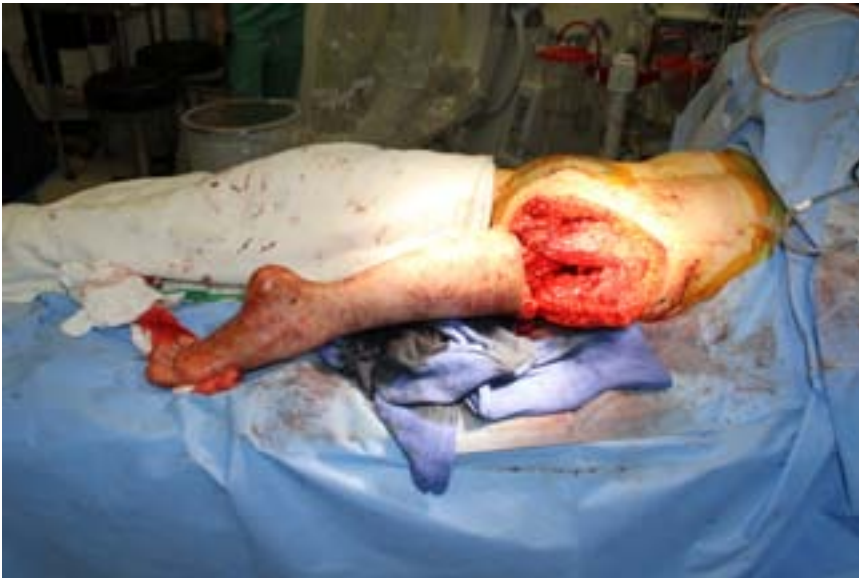

IMAGE 8

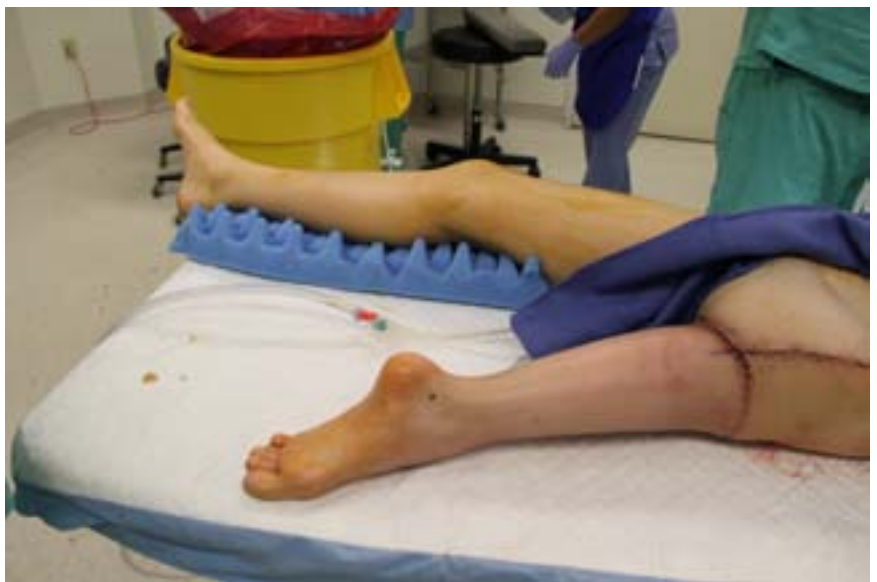

IMAGE 9



# PHYSIATRIST'S VOICE

NEWSLETTER

DECEMBER 2018

ARTICLE BY DR LICHTBLAU  
CONGENITAL FEMORAL DEFICIENCY

(CONTINUED FROM PREVIOUS PAGE)



IMAGE 10



# PHYSIATRIST'S VOICE

NEWSLETTER

DECEMBER 2018

JOB OPPORTUNITIES

## JOB OPPORTUNITIES

**Jacksonville area** – Outpatient. Develop an outpatient practice with your own design. Stable, solid system with an amazing reputation. Stimulating, supportive environment. Collegial environment with many inpatient physiatrists.

**Pensacola area** – Interventional. Work with a nationally-recognized leader in orthopaedic and sports medicine care. Enticing signing bonus + generous relocation allowance. Enjoy the beach and a vibrant, historic downtown district.

**Destin and Pensacola areas** – Rehab and SNF services. Work with a national rehab leader and a national hospital leader. Comprehensive benefits. Enjoy the beach!

**Southeastern FL** - Practice Purchase With the rapid growth of the area and the sound patient referral base, this practice provides an excellent opportunity. You can either run the practice yourself or as a satellite office. Excellent growth potential. The current owner has achieved top-line growth without a material investment into business development or marketing. This doctor is selling his patient load, transfer of insurance contacts, etc.

Jacksonville, Jupiter, Tampa and Miami – SNF services. Sign-on bonus. 5 day work week at a beautiful facility. No evenings, no weekends, no call. Flexible work schedule at a great location. Full case load.

Thank you,  
Linda Farr  
Farr Healthcare, Inc.  
888-362-7200  
717-395-2711 cell  
farrhealth@comcast.net  
www.farrhealthcare.com